Anatomy of Digestive System
Mouth, Palate, Pharynx, Oesophagus

Prof Dr Mohamed El-Badry Mohamed
Professor and Head of Human Anatomy and Embryology Department,
Faculty of Medicine, Merit University
Professor of Human Anatomy and Embryology Department,
Faculty of Medicine, Assiut University

Objectives of the of the Lecture

By the end of the lecture the student should be able to:

- Define the mouth
- Mention the organs forming the gastrointestinal tract
- Describe anatomy of the mouth
- How many milk teeth are present in the mouth?
- How many Name the salivary glands
- permanent teeth are present in the mouth?
- Describe anatomy of the tongue
- Describe anatomy of the oropharynx
- Describe anatomy of the oesophagus?
- Name the constrictions of the oesophagus and what is their clinical importance?

DIGESTIVE SYSTEM

- Consists of all the organs which participate in the process of digestion that starts with entry of food into the mouth to exit as stools from the anus

These organs are:

1. Organs of digestive tube: mouth, pharynx, oesophagus, stomach, intestine, anus
2. Salivary glands: parotid, submandibular, sublingual
3. Liver, gall bladder, pancreas

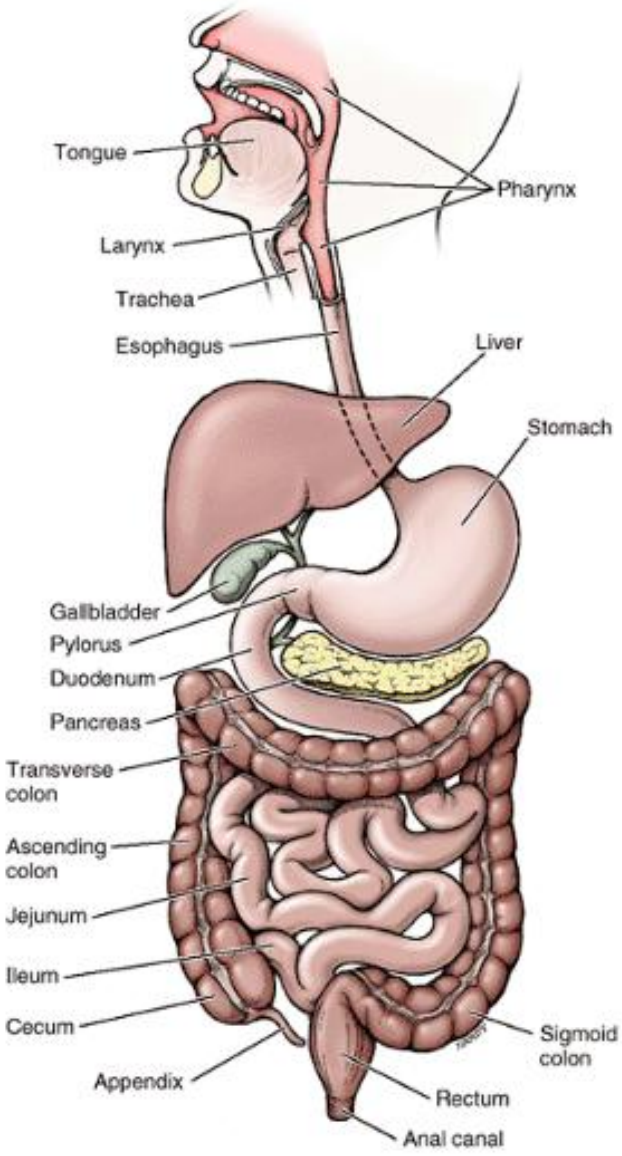

THE MOUTH

Definition: Beginning of the digestive system

Extensions:

- From the lips to the oropharyngeal isthmus (junction of the mouth with the pharynx)

Subdivisions Of The Mouth:

1. Vestibule Of The Mouth: Slit like space

Lies between: Lips and cheeks (externally) and gums and teeth (internally)

Communicates with:

The exterior through the oral fissure

The mouth proper behind the third molar tooth on each side, when the jaws closed

Cheek: Forms lateral wall of vestibule, made up of *buccinator;* covered on outside by buccopharyngeal fascia and skin and lined by mucous membrane.

Opposite upper second molar tooth: Small papilla present on mucous membrane, marking *opening of duct of parotid gland*.

2. Mouth Cavity Proper:

- **Lies within**: Alveolar arches, gums and teeth.

Has:

Roof: Formed by palate (hard and soft)

- **Floor**: Anterior two thirds of tongue.

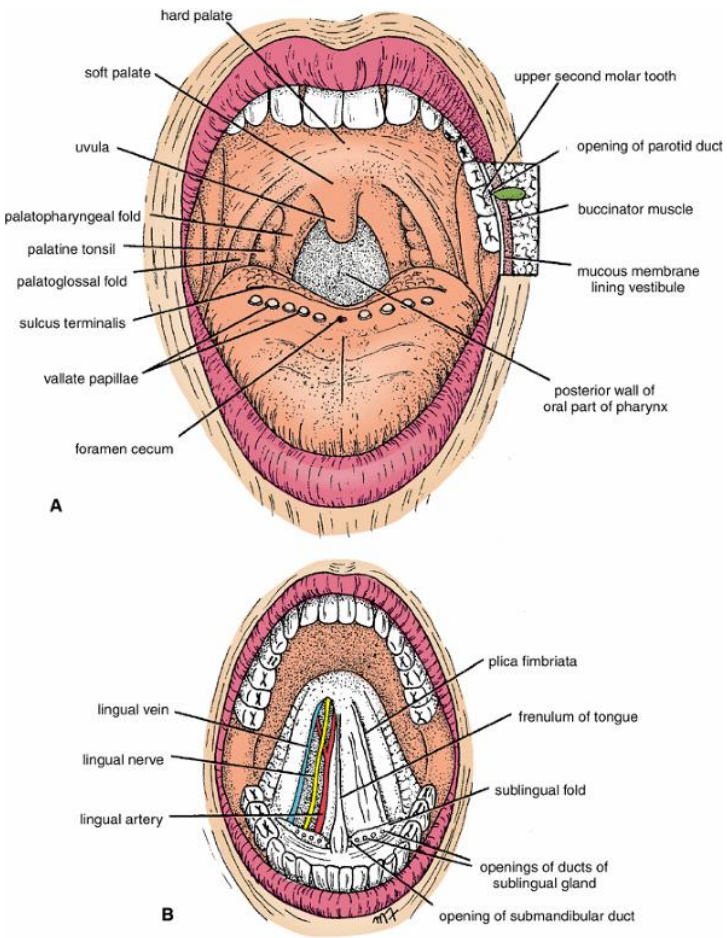

Frenulum of the Tongue:

- Fold of mucous membrane, in the midline, connects under surface of the tongue to floor of the mouth.
- **On its each side**: Sublingual fold for *sublingual salivary gland.*

TEETH

1. Milk teeth:

- 20 temporary teeth
- Starts arising at 6th month till 2nd year old age.

2. Permanent teeth:

- 32 permanent teeth Starts arising at 6th year till adult age.
- Third molar (Wisdom tooth) around 18 years.

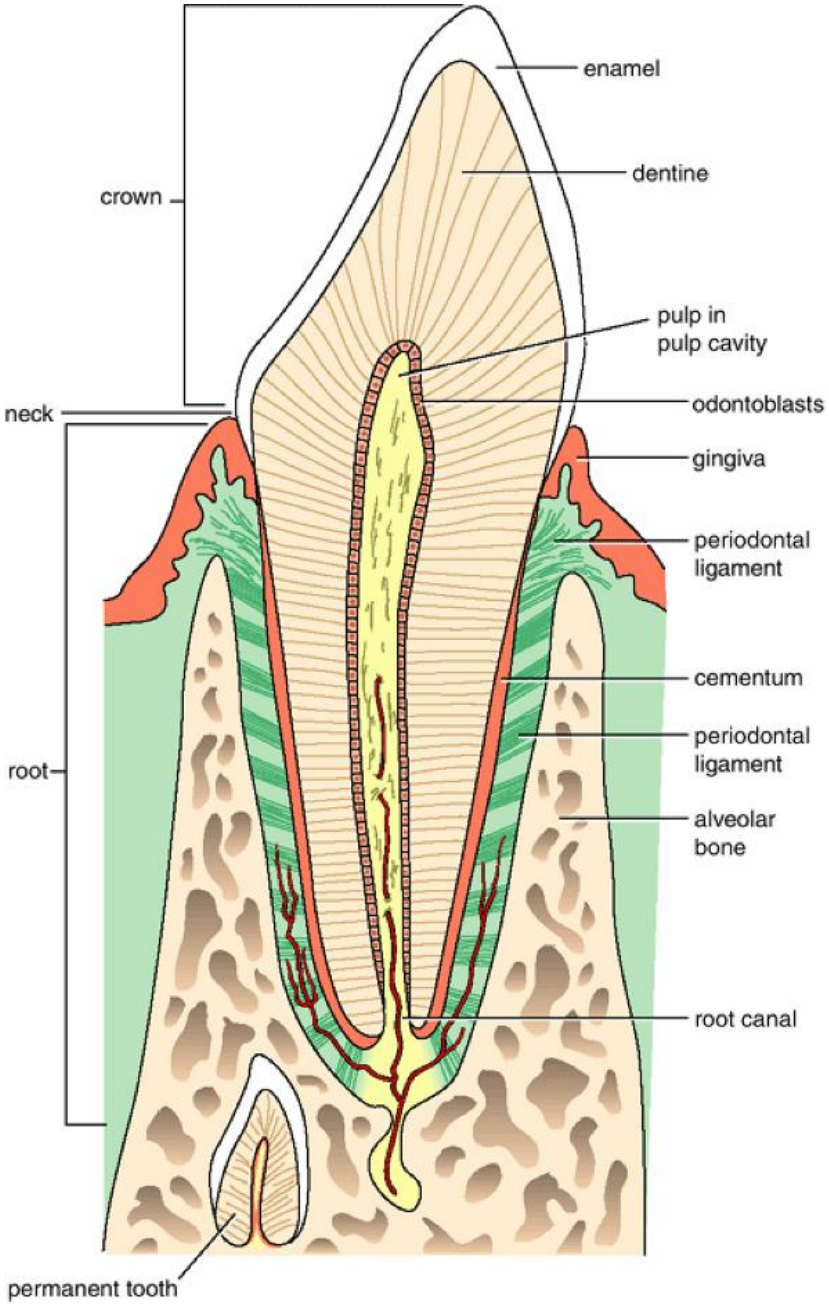

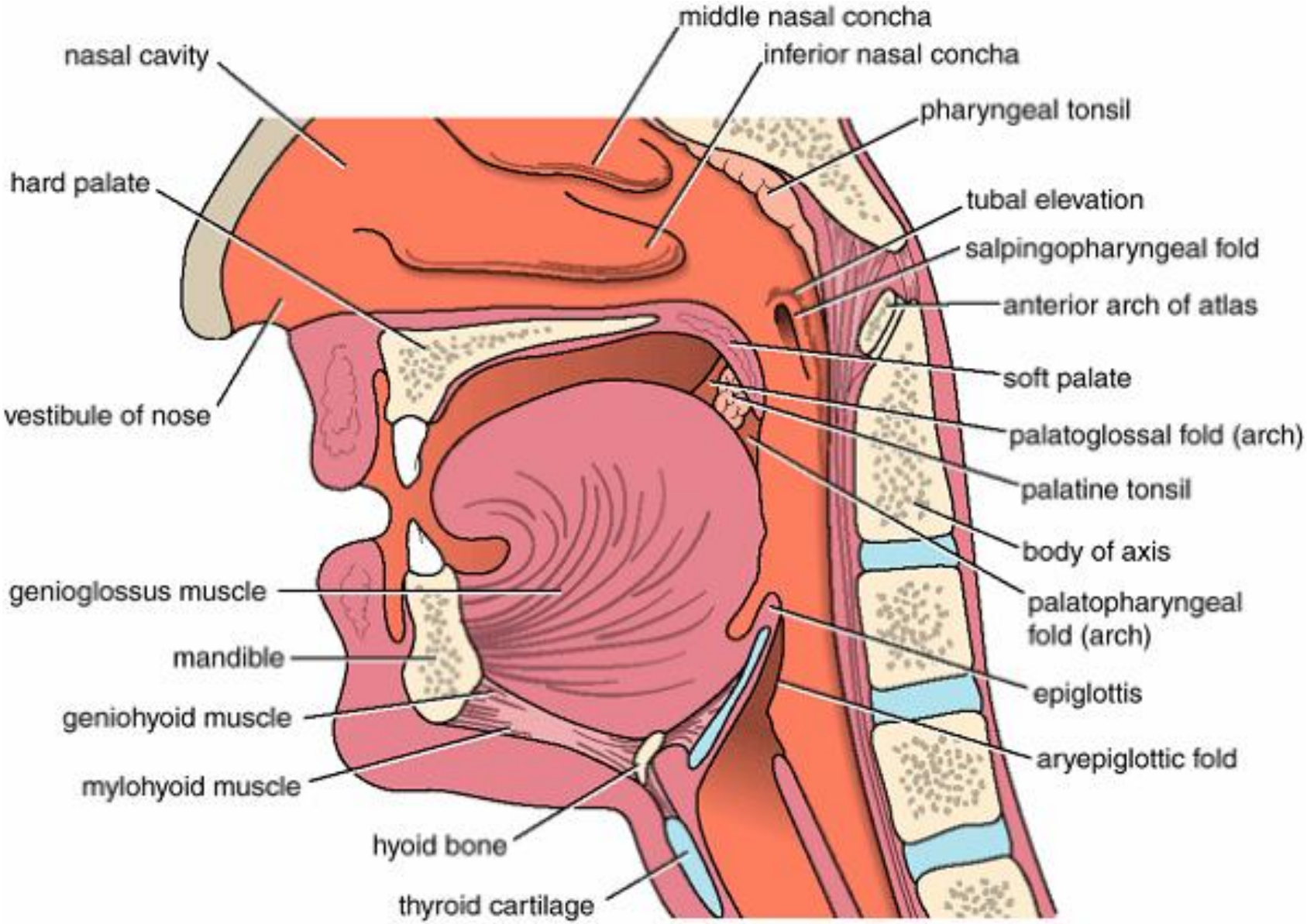
middle nasal concha
nasal cavity
inferior nasal concha
pharyngeal tonsil
hard palate
tubal elevation
salpingopharyngeal fold
anterior arch of atlas
soft palate
vestibule of nose
palatoglossal fold (arch)
palatine tonsil
body of axis
genioglossus muscle
palatopharyngeal fold (arch)
mandible
epiglottis
geniohyoid muscle
aryepiglottic fold
mylohyoid muscle
hyoid bone
thyroid cartilage

Sensory nerves of mucous membrane of mouth:

Roof:

1. Greater palatine nerve

2. Nasopalatine nerve

. Nerve fibers travel in the maxillary nerve

Floor:

1.Lingual nerve: Branch of mandibular nerve

2. Taste fibers of chorda tympani nerve, branch of the facial nerve

Cheek:

Buccal nerve: Branch of mandibular nerve

TONGUE

•Mass of striated muscles covered with mucous membrane.

•Anterior two-thirds lie in the mouth

•Posterior third lies in the pharynx

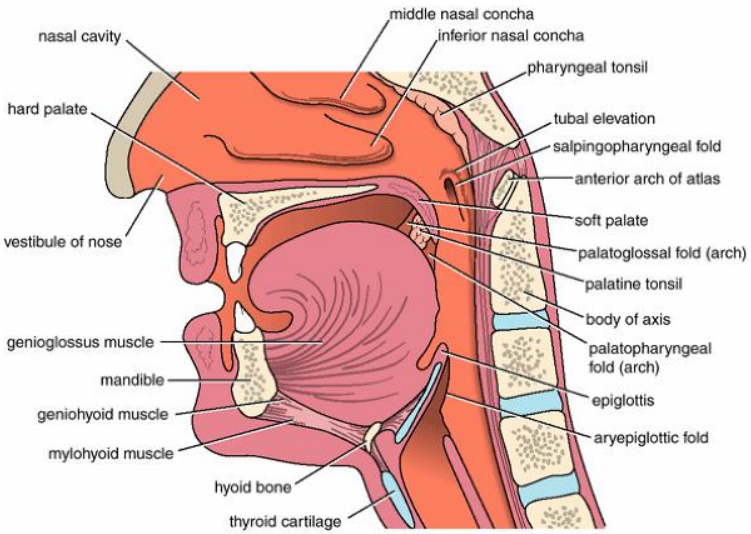

The muscles attach the tongue to:

Above: Styloid process and soft palate

Below: Mandible and hyoid bone

Mucous Membrane of the Tongue:

Upper surface of the tongue: **Divided into:**

•Anterior and posterior parts by V-shaped sulcus; *sulcus terminalis (*its apex projects backward and marked by *foramen cecum.*

Types of papillae on upper surface of anterior two-thirds of tongue:

1. Filiform papillae:

- Very numerous
- Form small conical projections.

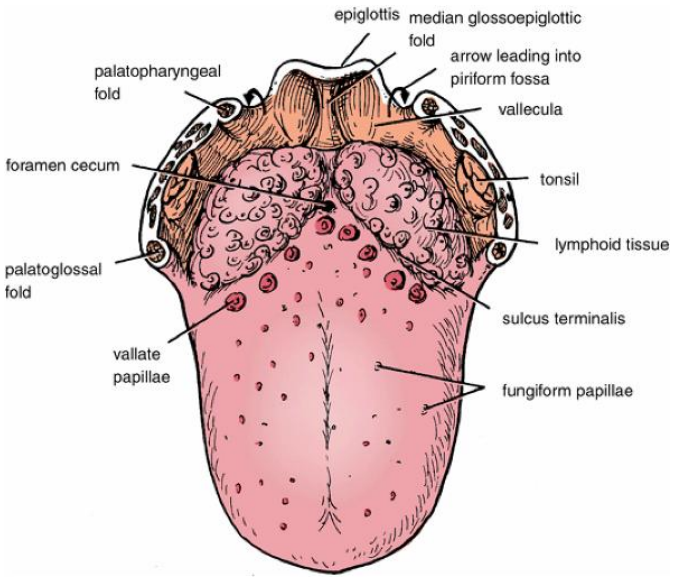

2. Fungiform papillae:

- Less numerous than filiform papillae
- Scattered on sides and apex of the tongue
- Mushroom-shaped.
- Has vascular connective tissue core.

3. Vallate papillae (10-12 in number):

- Situated in a row in front of sulcus terminalis
- Each papilla about 2 mm in diameter
- Protrudes slightly from the surface
- Surrounded by taste buds.

Mucous membrane of posterior third of tongue:

- Devoid of papillae
- Has nodular irregular surface caused by underlying lymph nodules (lingual tonsil).

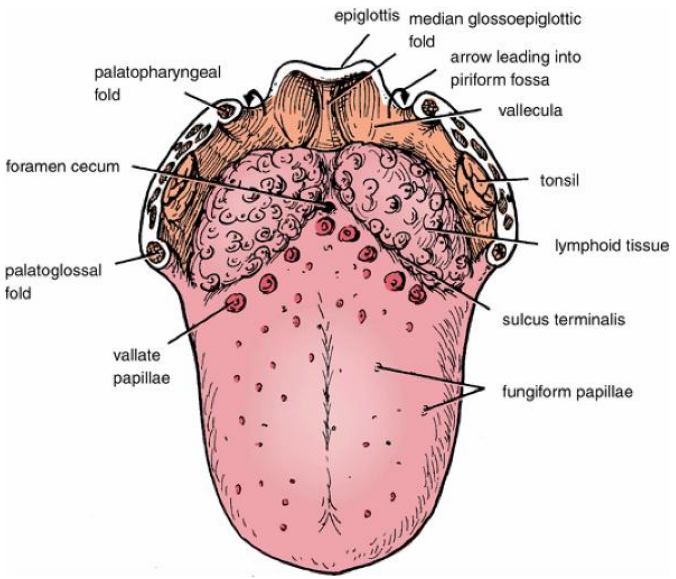

Mucous membrane of inferior surface of tongue:

Frenulum of the tongue:

- Fold of mucous membrane, in the mid line anteriorly, connecting under surface of the tongue to floor of mouth

Deep lingual vein: Can be seen on lateral side of frenulum.

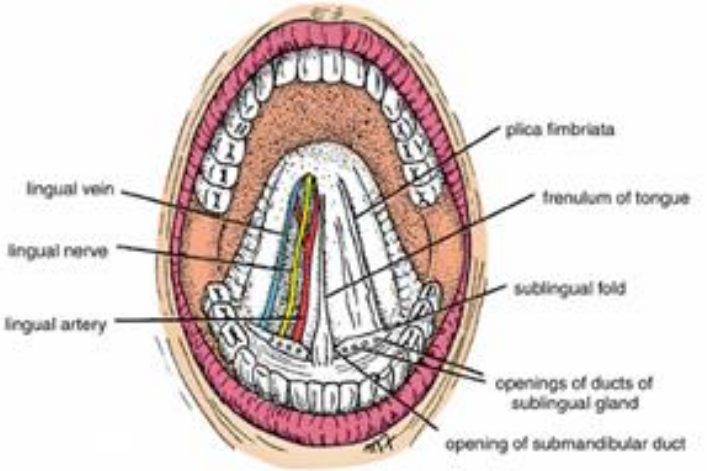

Muscles of the Tongue: 2 types:

I. Intrinsic Muscles:

- Confined to the tongue, not attached to bone
- Consist of:

1. Longitudinal fibers
2. Transverse fibers
3. Vertical fibers

Nerve supply: Hypoglossal nerve

Action: Alter the shape of the tongue

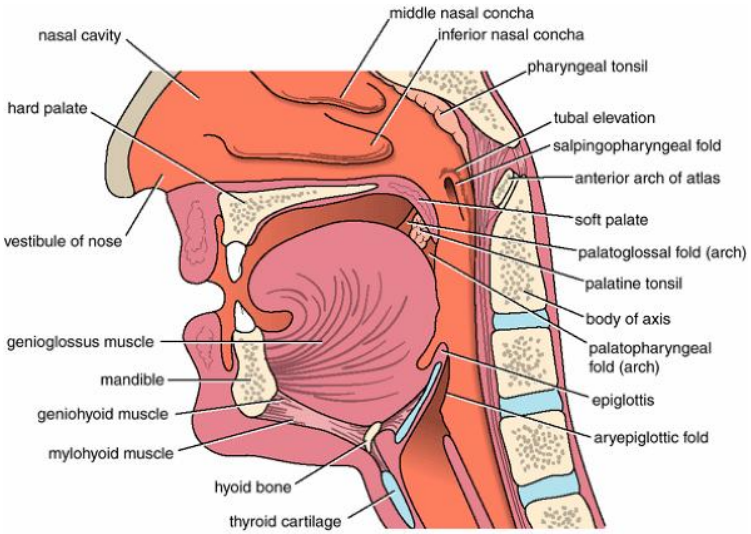

II. Extrinsic Muscles of the tongue:

- Attached to bones and soft palate
- Consist of:

1. Genioglossus
2. Hyoglossus
3. Styloglossus
4. Palatoglossus

Blood Supply of the Tongue:

Arterial supply:

1. Lingual artery
2. Tonsillar branch of facial artery
3. Ascending pharyngeal artery

Veins drain into: Internal jugular vein

Lymph Drainage of the Tongue:

- **Tip of the tongue**: Submental lymph nodes.
- **Remainder of anterior two-thirds**: Submandibular and deep cervical nodes on both sides.
- **Posterior third of tongue**: Deep cervical lymph nodes on both sides.

Sensory Innervation of the Tongue:

Mucous membrane covering anterior two-thirds

Lingual nerve: General sensation.

Chorda tympani: Taste sensation except vallate papillae.

Mucous membrane covering posterior third:

Glossopharyngeal nerve:

General sensation and taste including vallate papillae.

Motor supply of the tongue:

All the muscles of tongue are supplied by **hypoglossal nerve** except palatoglossus which is supplied by **cranial part of accessory nerve.**

Movements of the Tongue and Muscles Doing:

1. Protrusion:

- Genioglossus muscles
- On both sides acting together

2. Retraction:

1. Styloglossus muscles
2. Hyoglossus muscles
- On both sides acting together

3. Depression:

1. Hyoglossus muscles
2. Genioglossus muscles
- On both sides acting together

4. Retraction and elevation of posterior third:

1. Styloglossus muscles
2. Palatoglossus muscles
- On both sides acting together

5. Shape changes of the tongue:

- Modified in shape by action of its intrinsic muscles

SOFT PALATE

- **Mobile fold.**
- **Attached to posterior border of the hard palate.**
- **Covered on its upper and lower surfaces by mucous membrane (*numerous mucous glands on both sides and collections of lymphoid tissue in submucosa*).**

- **Uvula:**
- **Conical projection in midline of its free posterior border.**

Contents of the soft palate:

1. Aponeurosis
2. Muscle fibers
3. Lymphoid tissue
4. Glands
5. Vessels
6. Nerves

Palatine Aponeurosis:

1) Fibrous sheet
2) Attached to posterior border of hard palate
3) Expanded tendon of tensor veli palatini to enclose musculus uvulae

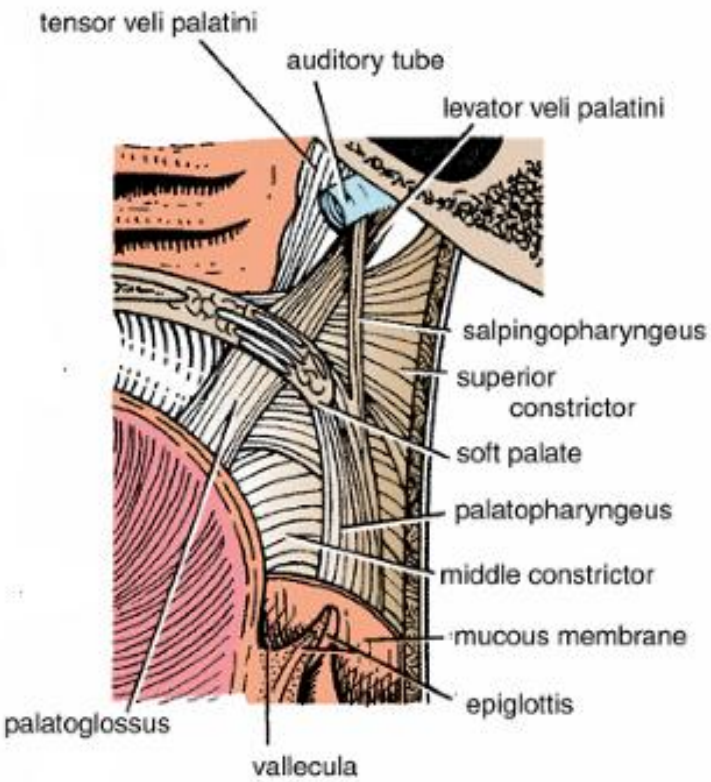

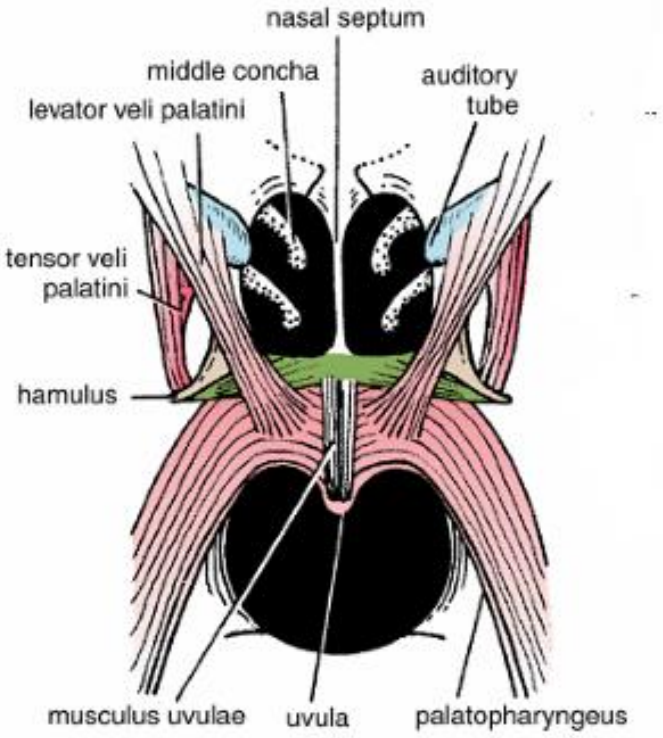

Muscles of soft palate:

1. Tensor veli palatini
2. Levator veli palatini
3. Palatoglossus
4. Palatopharyngeus
5. Musculus uvulae

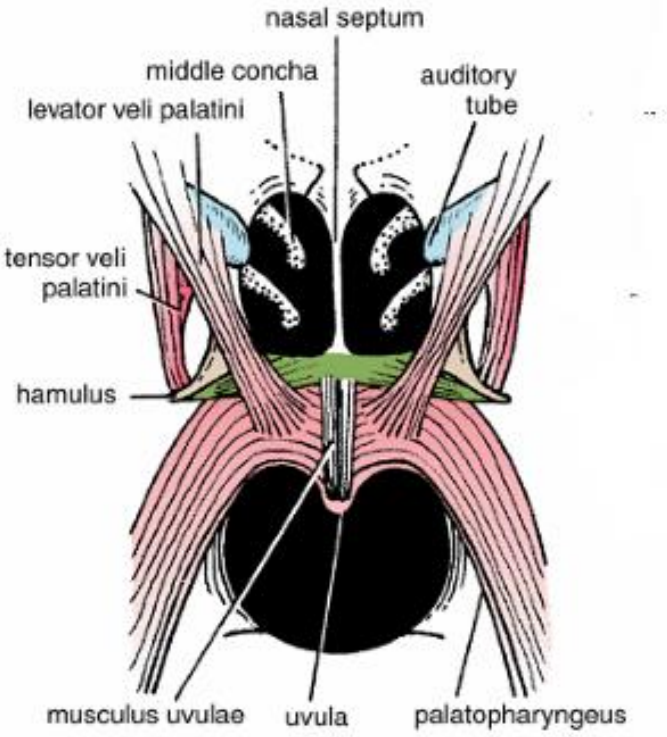

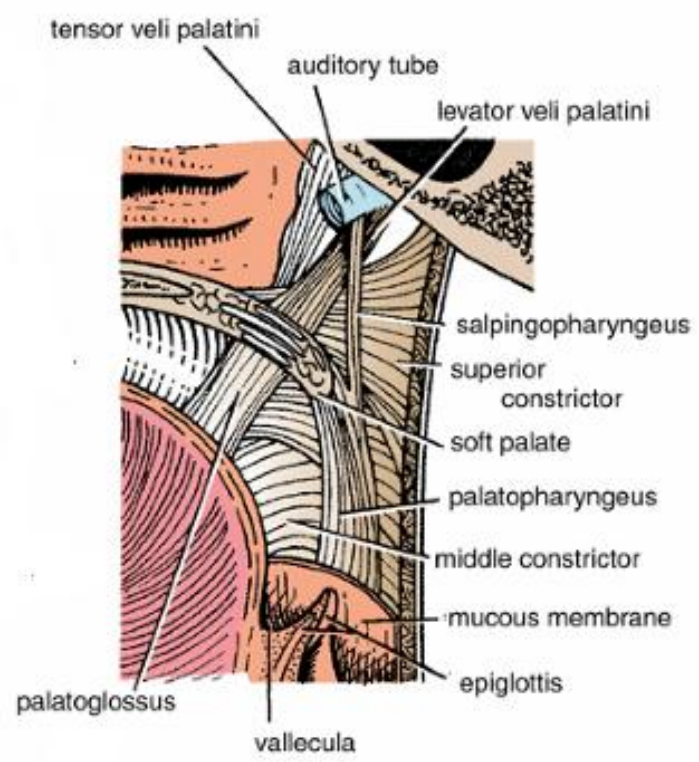

TENSOR VELI PALATINI

Origin:
1. Spine of the sphenoid
2. Auditory tube
3. Scaphoid fossa

Insertion: **Palatine aponeurosis**

Nerve supply:
- Nerve to medial pterygoid from mandibular nerve.

Action:
- The 2 muscles tighten soft palate, so, moved upward or downward as tense sheet.

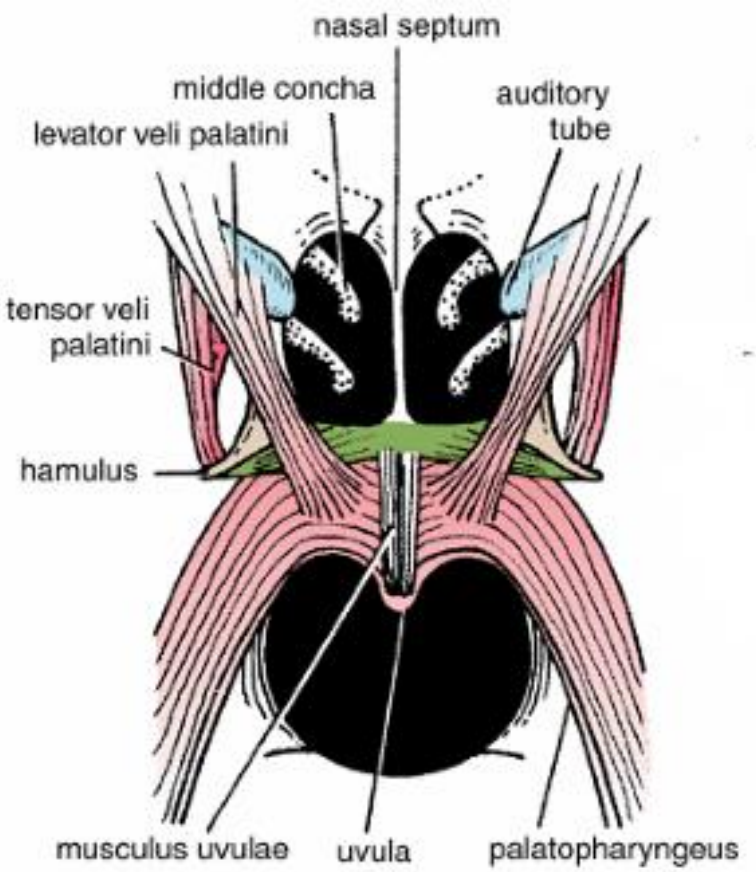

LEVATOR VELI PALATINI

Origin:

- Petrous part of temporal bone.
- Cartilage of auditory tube.

Insertion:

- Palatine aponeurosis

Nerve supply: Pharyngeal plexus.

Action: Raise the soft palate.

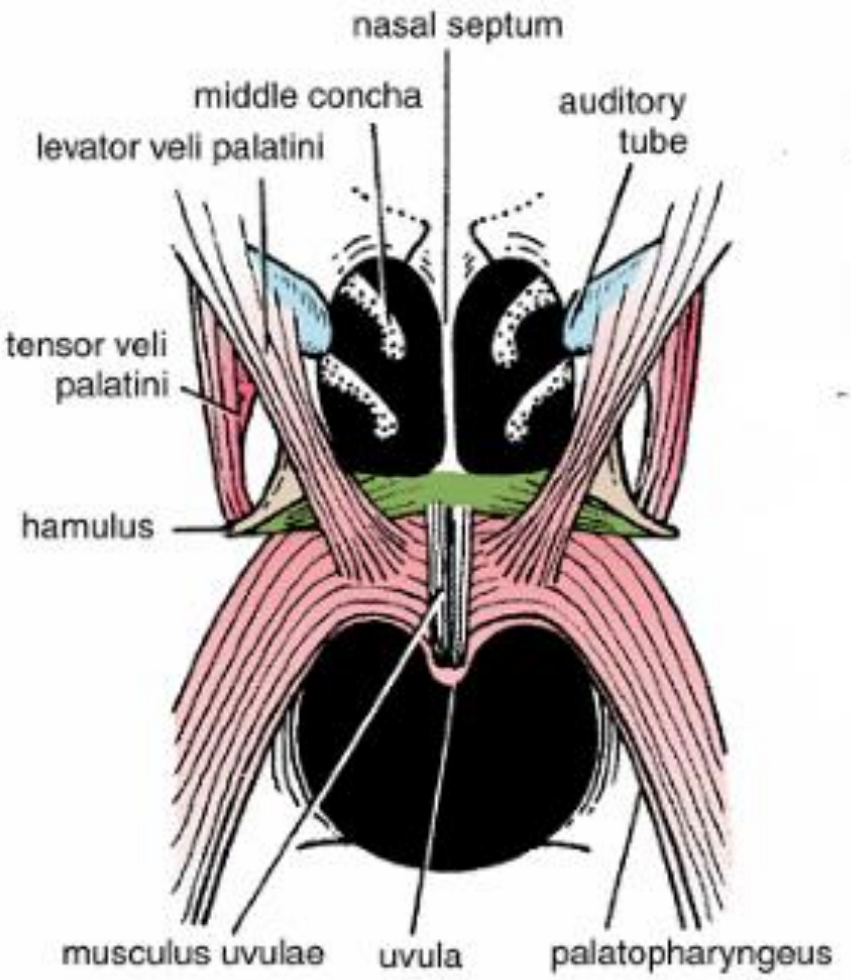

PALATOPHARYNGEUS MUSCLE

Origin:

1) Posterior border of the hard palate.
2) Palatine aponeurosis.

Insertion:

- Thyroid cartilage.

Nerve supply: Pharyngeal plexus

Action:

- Pulls wall of the pharynx upward
- Acting together: Pull palatopharyngeal arches toward the midline

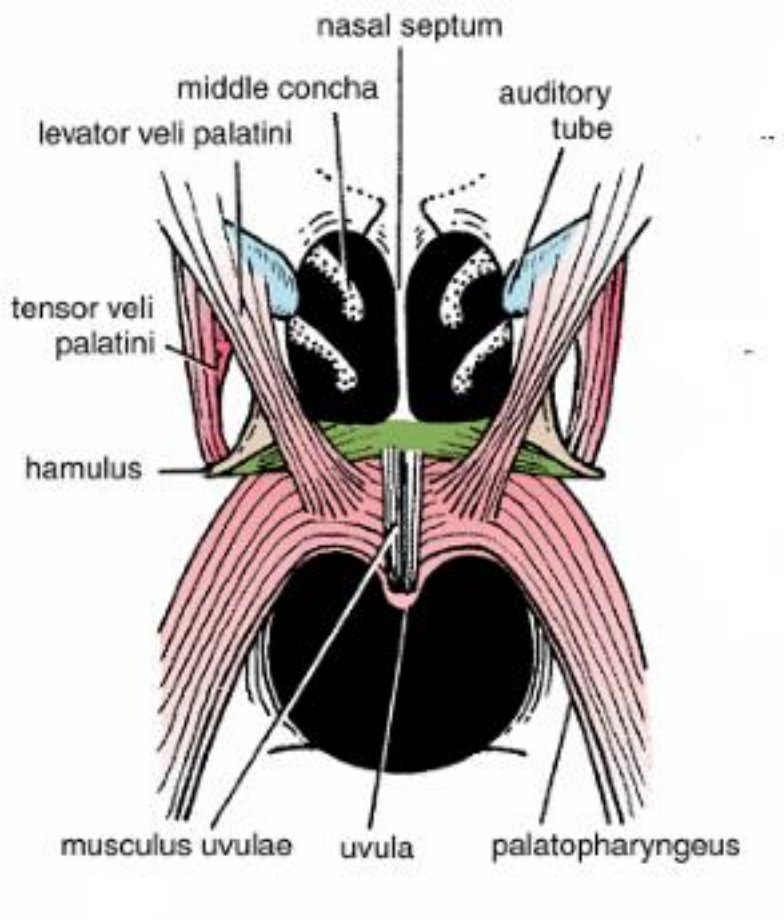

PALATOGLOSSUS MUSCLE

Origin: Palatine aponeurosis

Insertion: Side of the tongue

Nerve supply:

- **Pharyngeal plexus**

Action:

- **Pulls root of the tongue upward and backward.**
- **Both muscles contracting together: Cause palatoglossal arch to approach midline, thus oropharyngeal isthmus is narrowed**

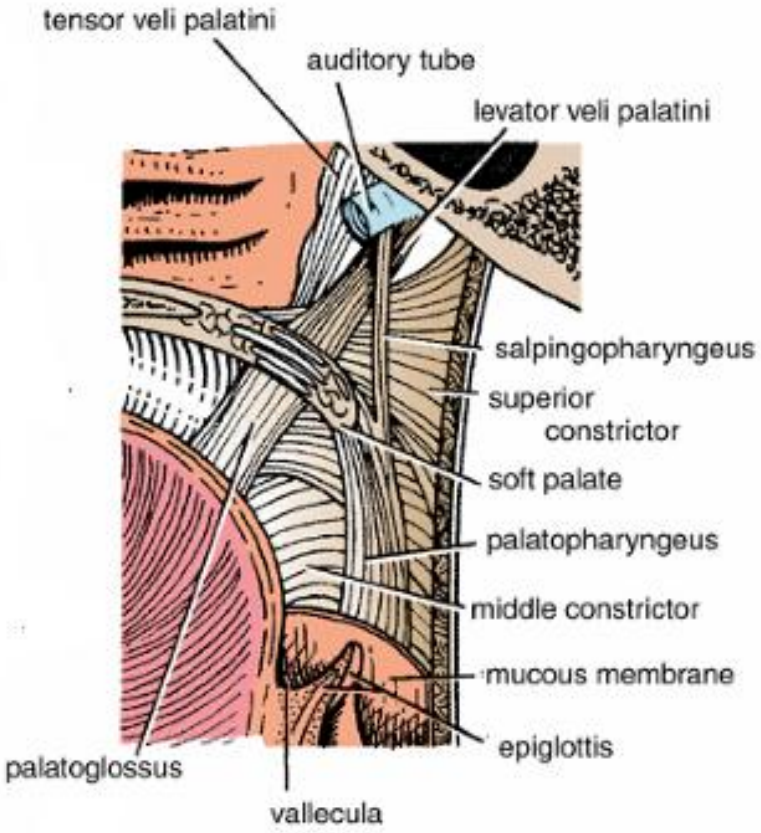

MUSCULUS UVULAE MUSCLE

Origin:

1) Hard palate
2) Palatine aponeurosis

Insertion:

- Mucous membrane of uvula

Nerve supply:

- Pharyngeal plexus

Action: Pulls up the uvula

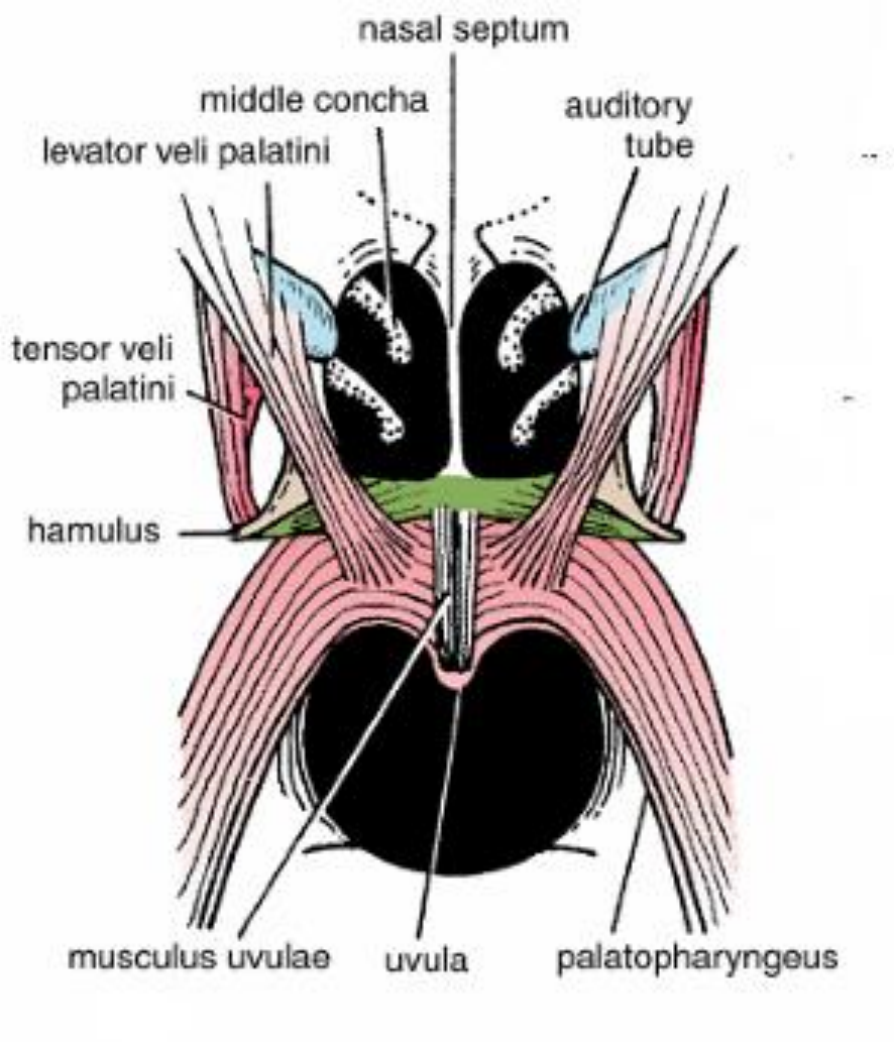

SALIVARY GLANDS:

1)Parotid glands
2)Submandibular glands
3)Sublingual glands
4)Numerous small glands scattered throughout the mouth cavity

PAROTID GLAND

Type And Position Of Parotid Gland

1) The largest of the salivary glands
2) Composed almost entirely of serous acini
3) Situated below external auditory meatus
4) Lies in deep hollow behind ramus of mandible and front sternomastoid muscle

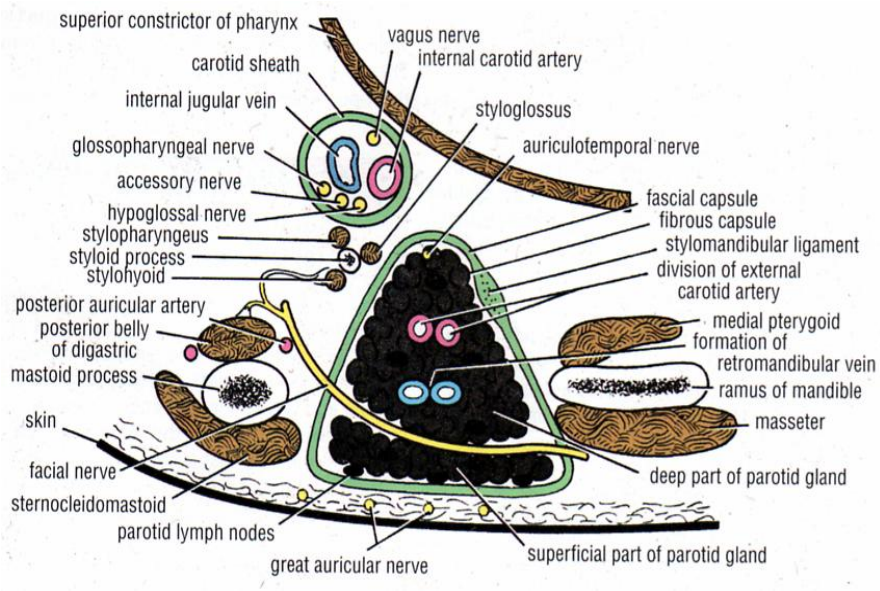

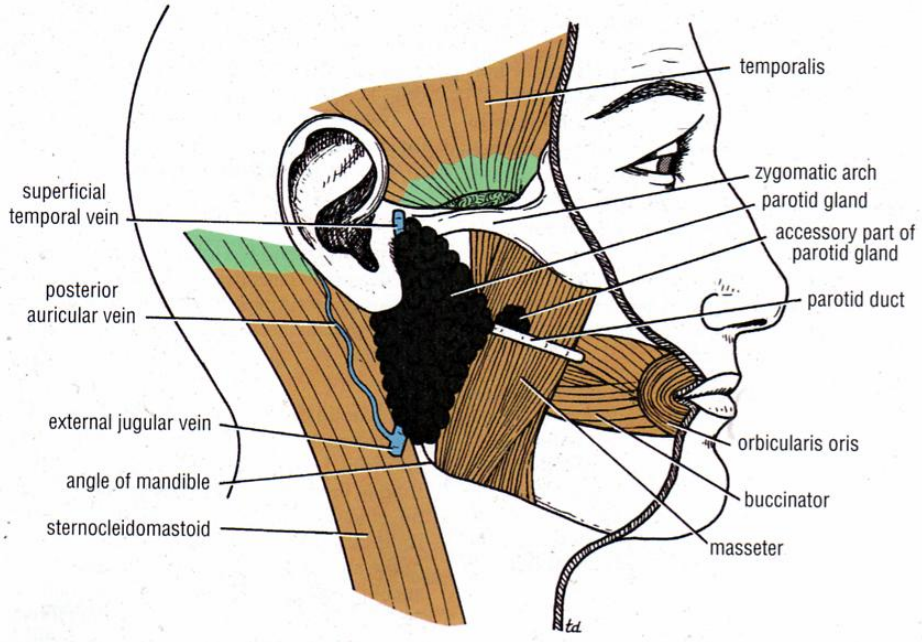

SUBMANDIBULAR GLAND

- Large salivary gland

Composed of: Mixture of serous and mucous acini

Lies: Partly undercover of body of mandible

Made up of:

1. Superficial part (large)
2. Deep part (small)

- Continuous with each other around posterior border of mylohyoid muscle.

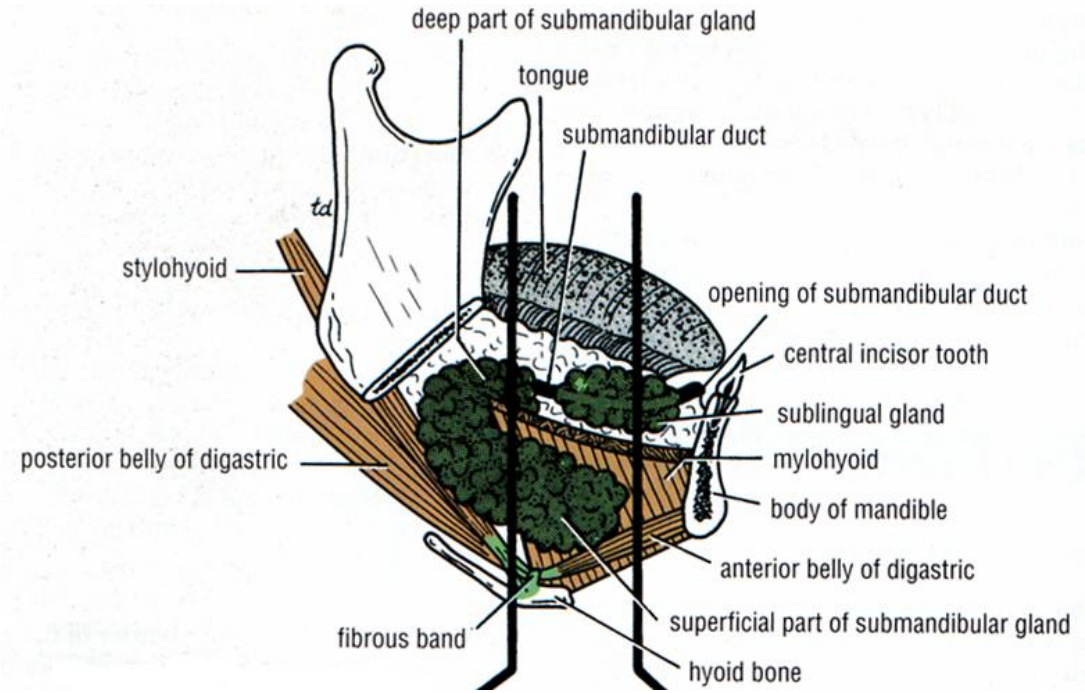

Sublingual Salivary Gland

Laterally:

- Submandibular fossa of medial surface of mandible.

Superiorly:

- Mucous membrane of floor of the mouth, elevated by the gland to form *sublingual fold.*

Inferiorly: Mylohyoid muscle

Sublingual Ducts:

- 8-20 in number
- The majority open into: The mouth on summit of sublingual fold.

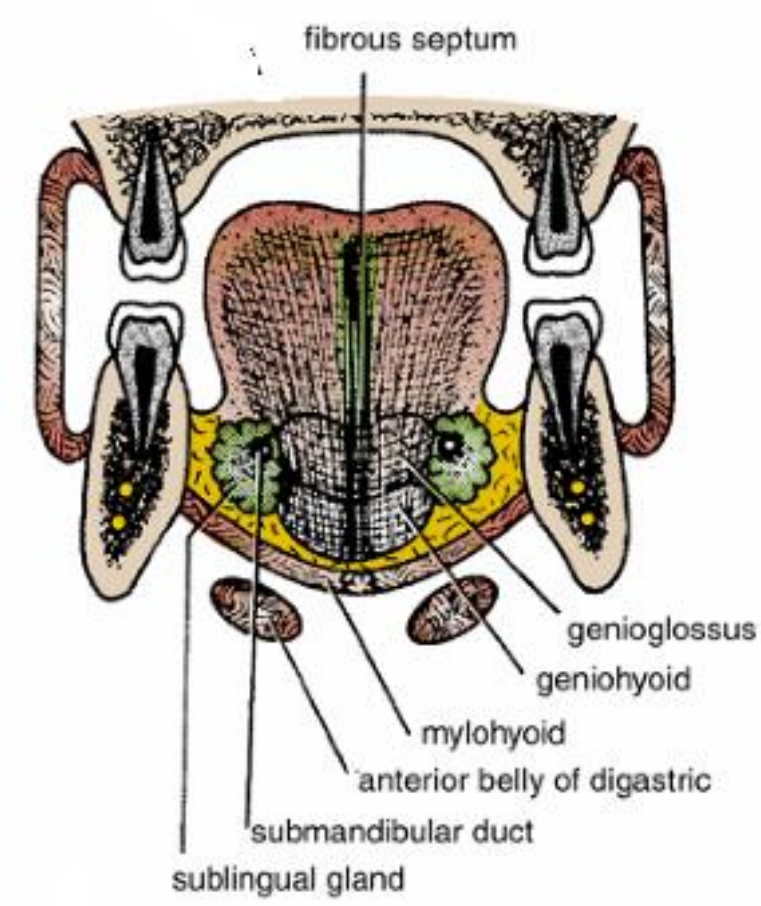

Blood Supply of Sublingual and Sublingual Salivary Glands:

Arteries: Branches of:

1. Facial artery
2. Lingual artery

Veins: Drain into:

1. Facial vein
2. Lingual vein

Lymph drainage: Lymph vessels drain into:

1. Submandibular lymph nodes
2. Deep cervical lymph nodes

Nerve supply of sublingual gland:

Parasympathetic secretomotor supply from:

- *Superior salivary nucleus of facial nerve*
- Nerve fibers pass to submandibular ganglion via chorda tympani and lingual nerves
- Postganglionic parasympathetic fibers pass to the gland via the lingual nerve

Postganglionic sympathetic fibers: Reach the gland as plexus of nerves around facial and lingual arteries.

PHARYNX

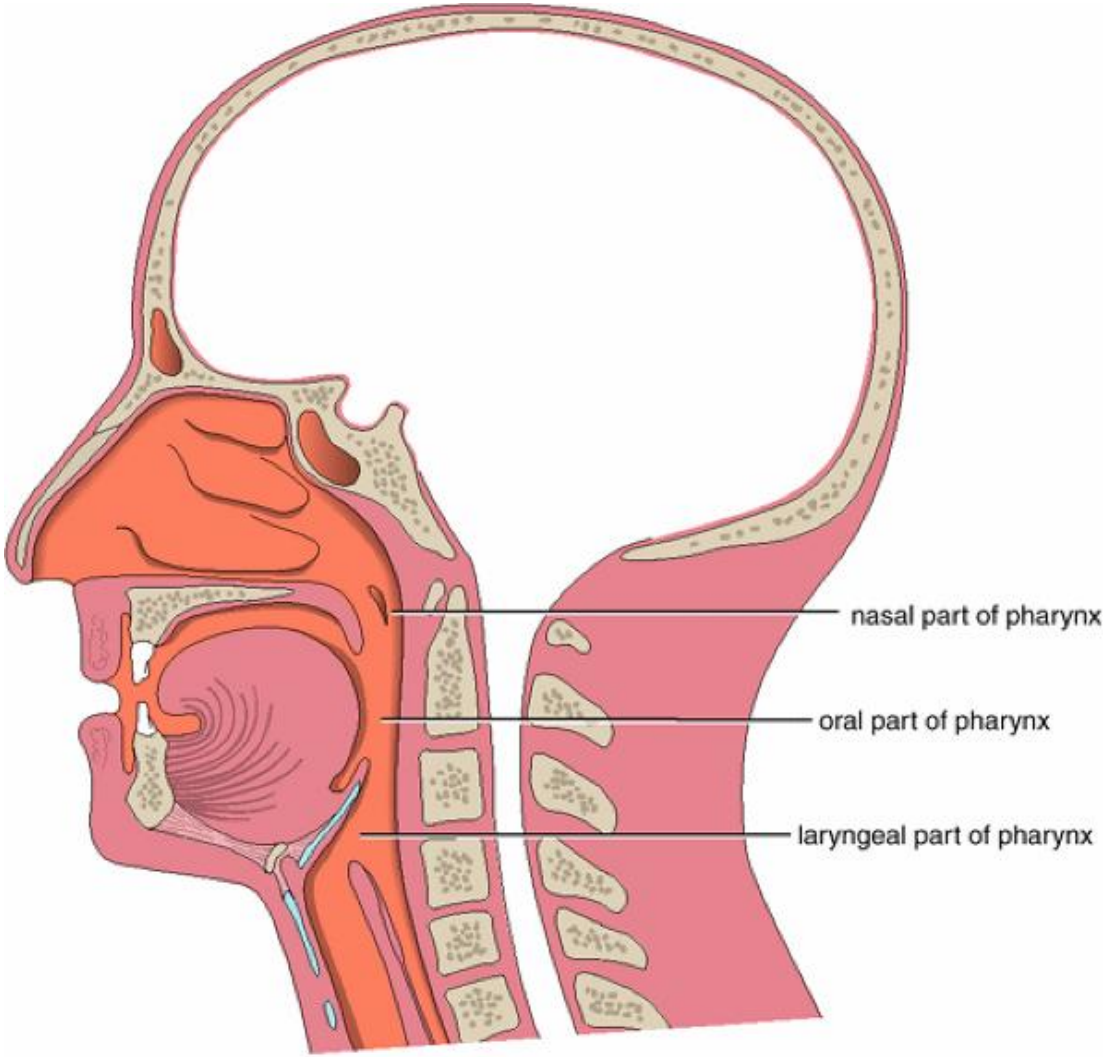
nasal part of pharynx
oral part of pharynx
laryngeal part of pharynx

Pharynx

- Muscular tube that extends from oesophagus (C 6) to base of skull.
- Anteriorly, pharynx opens into back of nose, mouth, and larynx.
- Pathway of food and air to oesophagus and larynx respectively.
- Comprised of three muscles:
- Superior, middle, and inferior pharyngeal constrictor muscles.
- Fan-like structures that stack one inside the other and interdigitate.
- Attached to side walls of 3 orifices into which pharynx opens anteriorly.
- All 3 muscles attach to median raphe (fusion of the muscles) as they fan out and attach to posterior wall of pharynx.

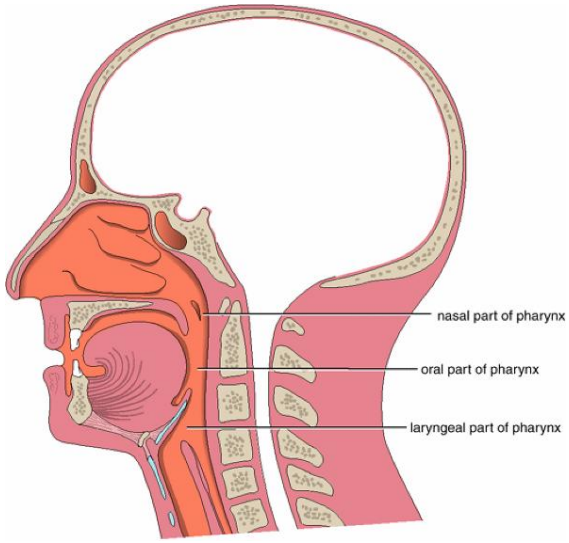

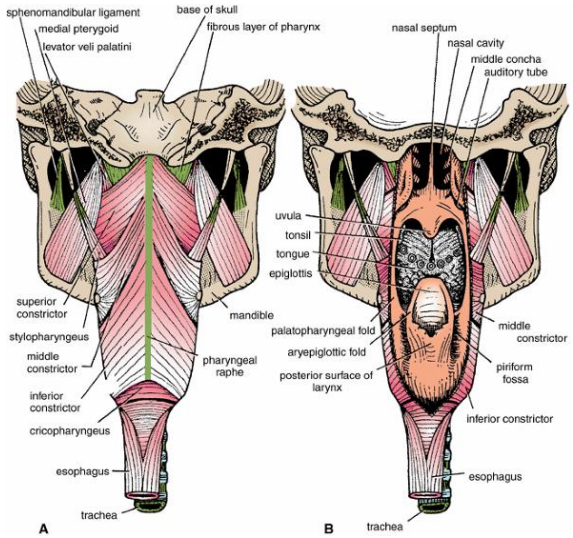

Oropharynx:

- Area behind mouth, between soft palate and hyoid bone, and is important in digestion and as part of immune response.
- Receives food boluses during swallowing and is part of conduit between mouth, laryngeopharynx and oesophagus.
- Involuntarily contracts on receiving food, squeezing the bolus into laryngopharynx and into oesophagus.
- Contains palatine tonsils, between palatoglossal and palatopharyngeal arches at back of throat.

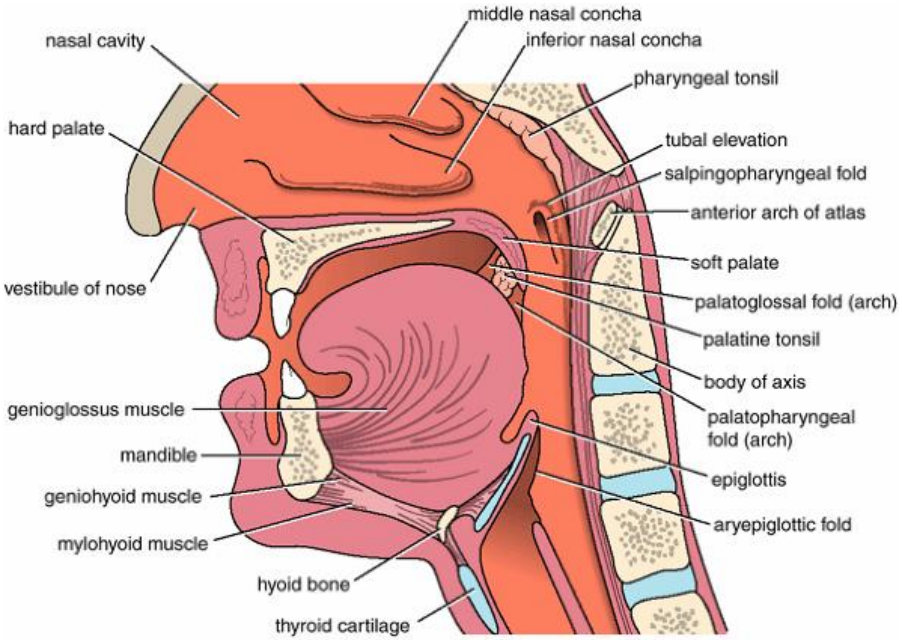

Laryngopharynx:

- Area behind larynx, from epiglottis;

C 3 end at start of oesophagus C 6.

- Waldeyer's Ring: Continuous lymphoid ring formed by palatine tonsils, (lymphoid tissue on dorsum of tongue), and adenoids (pharyngeal tonsil). Together, they act as one of first lines of defense in immune system.

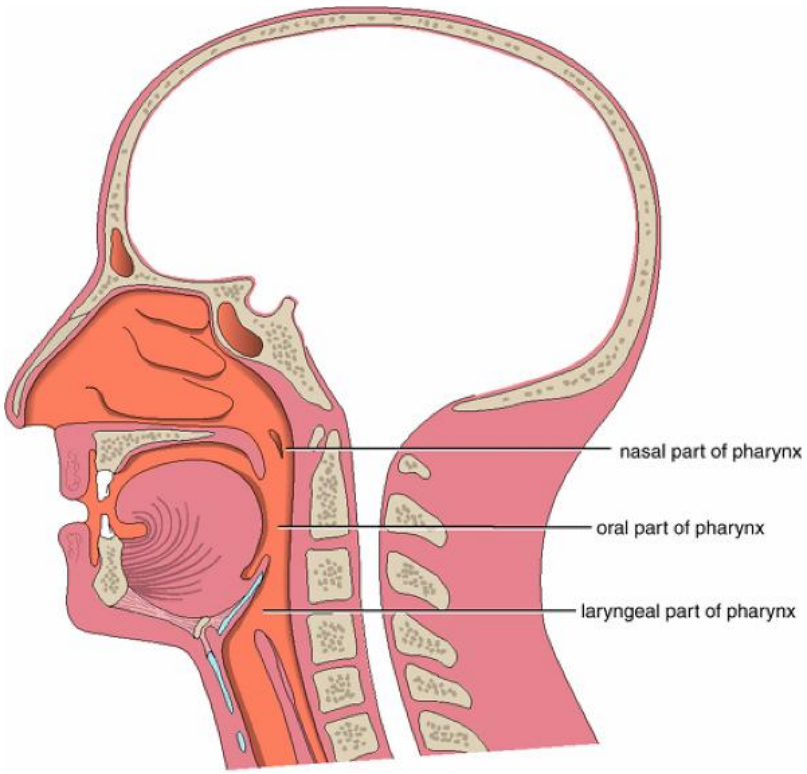

Blood supply and innervation of the pharynx

- **Branches from *external carotid (*Ascending pharyngeal, facial , lingual, maxillary*) and* superior thyroid arteries.**
- **Pharyngeal venous plexus drains into internal jugular vein.**
- **Sensory innervation: Cranial nerve IX (via pharyngeal branches) and cranial nerve V (via maxillary division), supplies nasopharynx.**
- **Motor innervation: Cranial nerve X (via pharyngeal branches).**

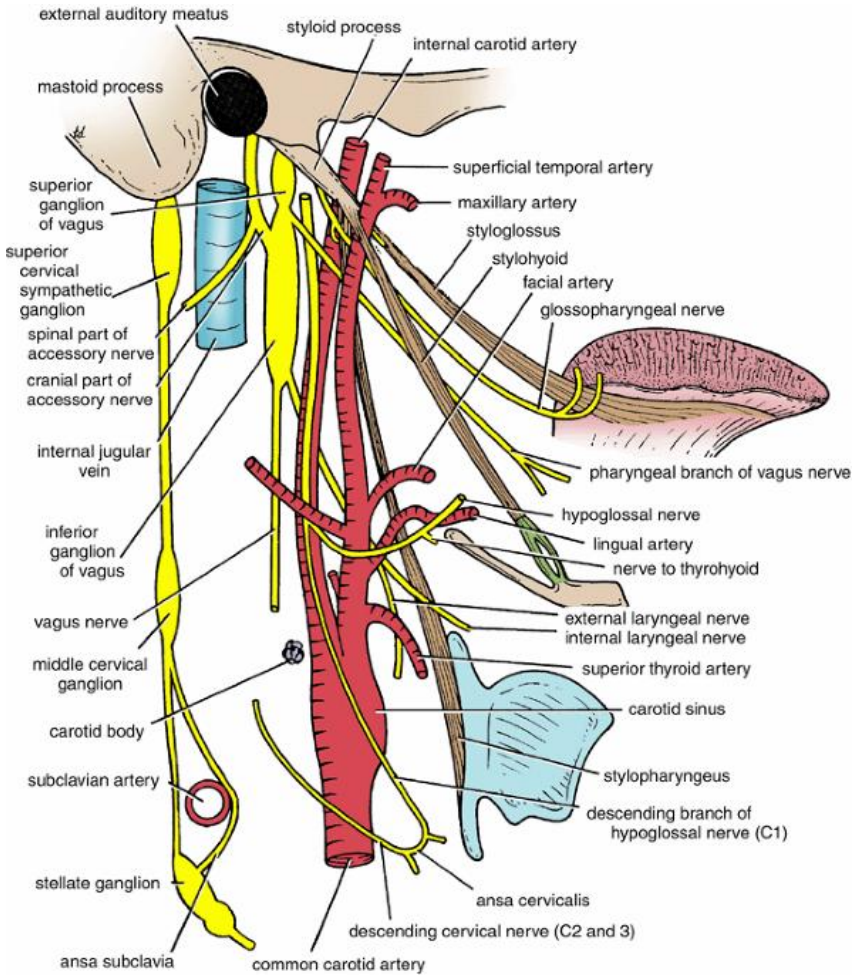

OESOPHAGUS

Tube about 10 inches (25 Cm) long.

BEGINNING:

- Continuous above with of pharynx.
- Opposite 6th cervical vertebra.

END:

- Passes through oesophageal opening of the diaphragm.
- At level of 10th thoracic vertebra.

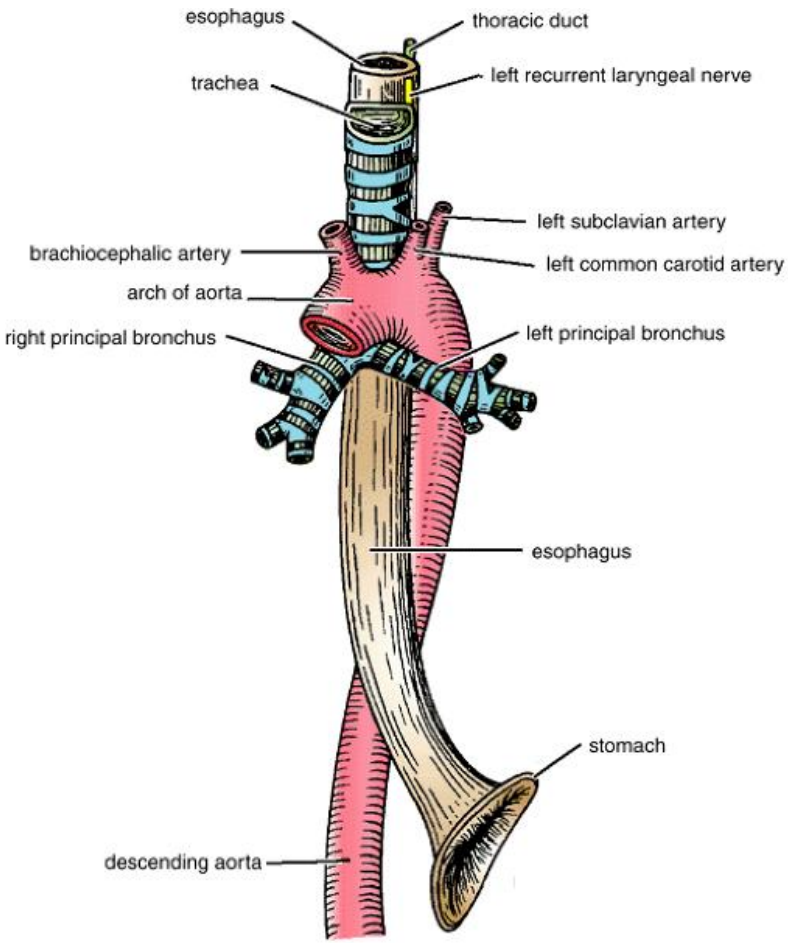

At opening into diaphragm oesophagus is accompanied by

1)2 vagi
2)Branches of left gastric vessels
3)Lymph vessels

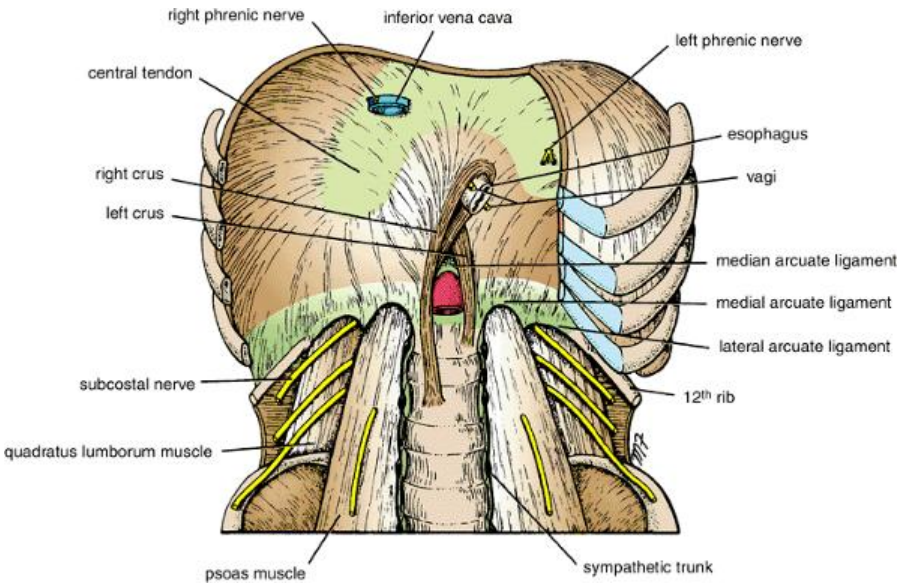

- Fibres from right crus of diaphragm pass around oesophagus as a sling (sphincter).

Oesophagus in the abdomen:

- Descends for about ½ inch.
- Enters the stomach (at level of T 11).
- Related to liver (anteriorly) and diaphragm (posteriorly).

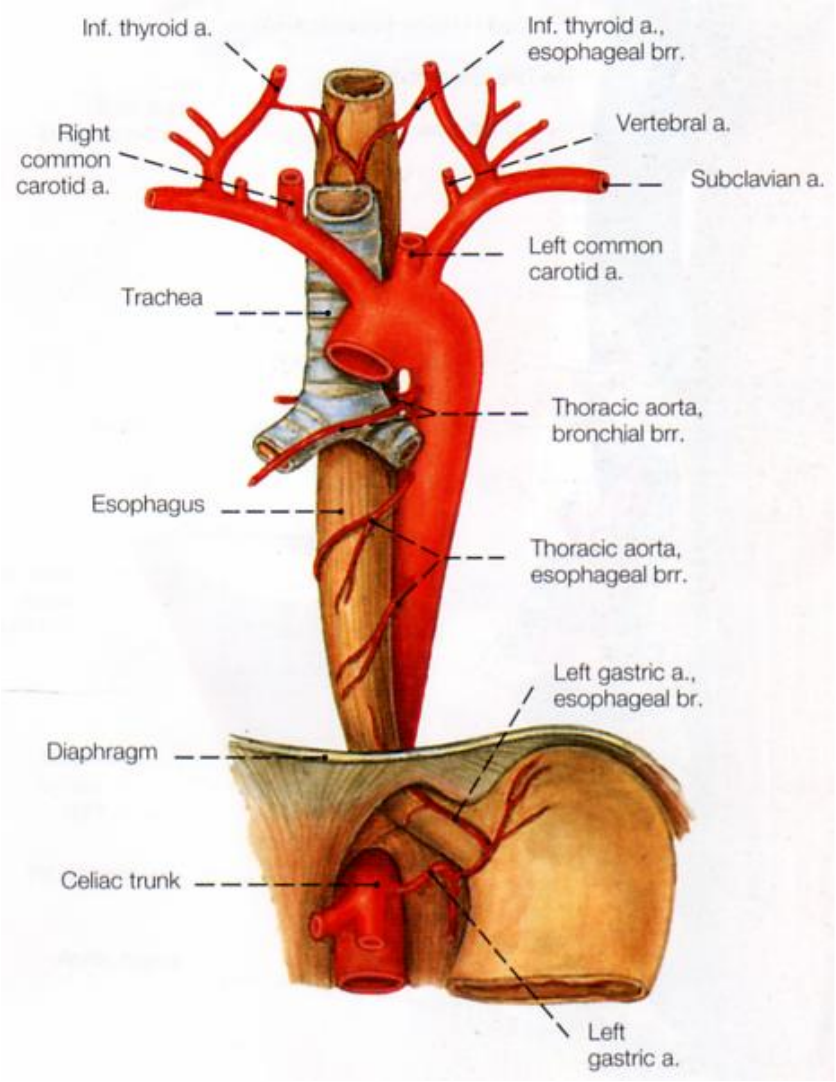

Arterial Supply of Oesophagus:

Cervical part:

- Inferior thyroid arteries

Thoracic part:

- Descending thoracic aorta.

Abdominal part:

- Left gastric artery.

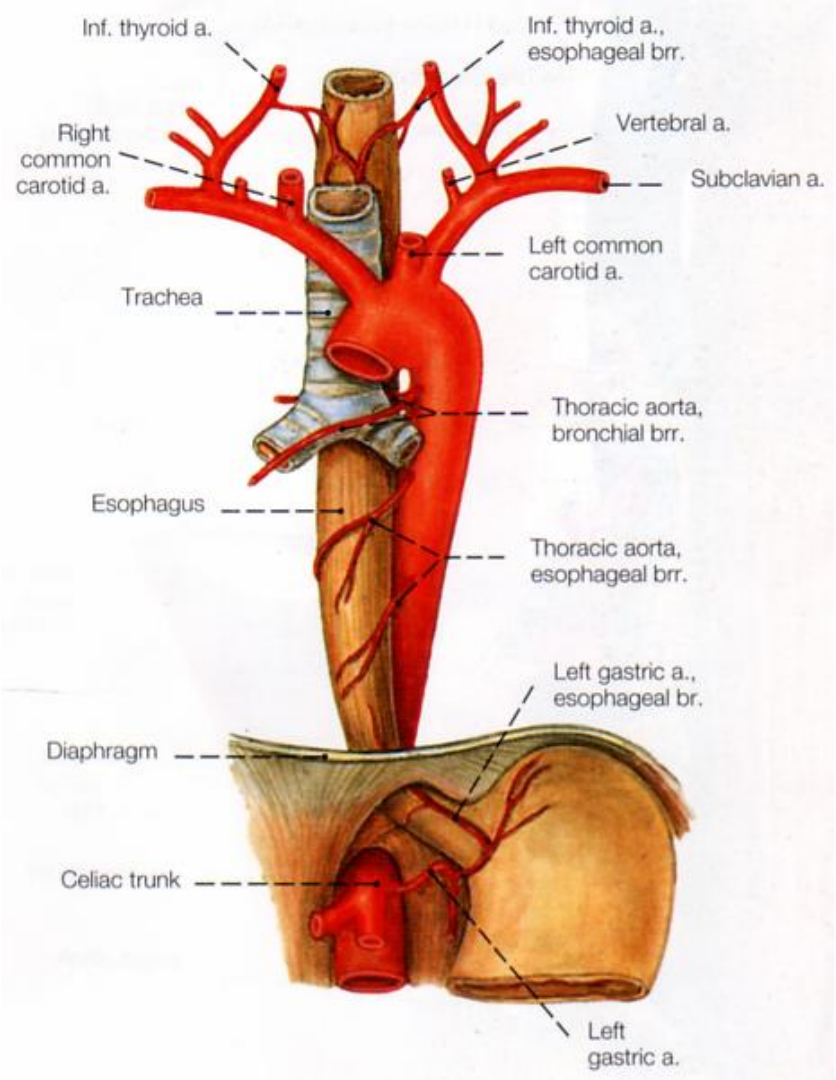

Venous Drainage of Oesophagus:

1)**Cervical part**: Inferior thyroid veins

2)**Thoracic part**: Azygos veins

3)**Abdominal part**: Left gastric vein (portal)

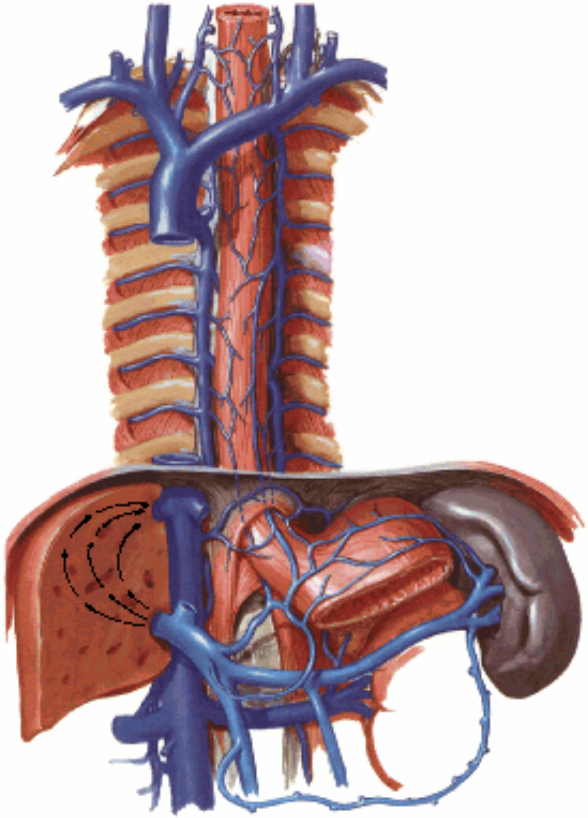

LYMPH DRAINAGE:

Cervical part:

- Deep cervical lymph nodes

Thoracic part:

- Superior and posterior mediastinal lymph nodes

Abdominal part:

- Lymph nodes along left gastric blood vessels to celiac lymph nodes

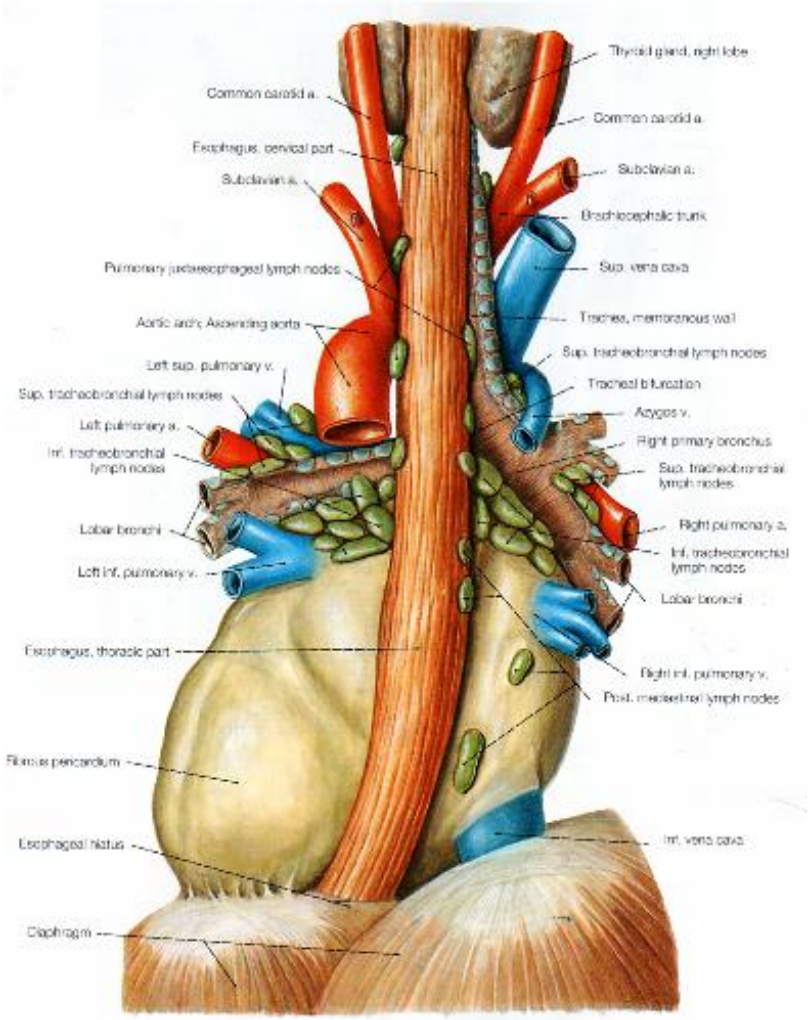

Nerve Supply of Oesophagus: (ANS)

Parasympathetic and sympathetic efferent and afferent fibres by:

1. Vagi
2. Sympathetic trunks

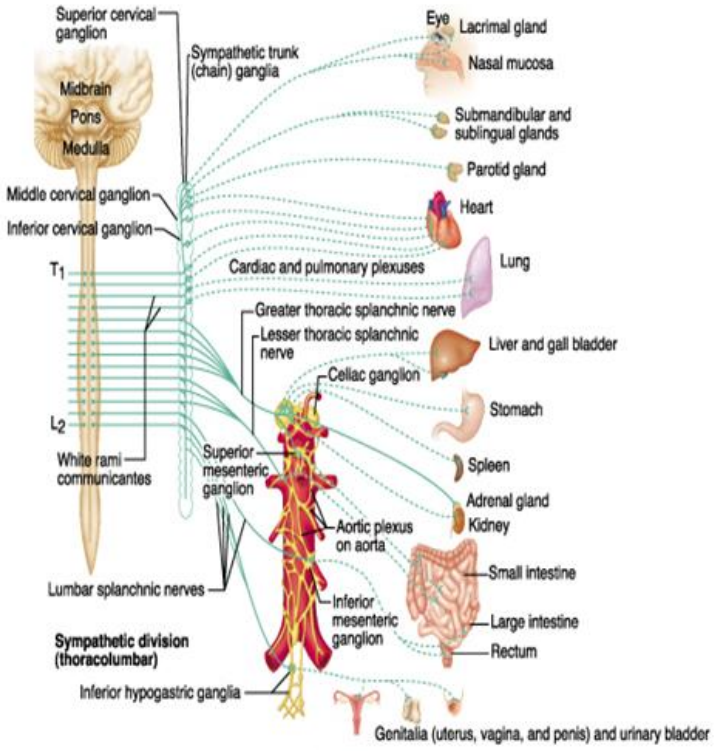

- **Oesophageal plexus:**
  Surrounds lower thoracic part of oesophagus

Constrictions of oesophagus:

3 anatomical and physiological

First constriction:

- Where pharynx joins *upper end*
- 6 inches from upper incisor teeth

Second constriction:

- Where *aortic arch and left bronchus* cross its anterior surface
- 10 inches from upper incisor teeth

Third constriction:

- Where oesophagus passes through *diaphragm* into stomach
- 16 inches from upper incisor teeth

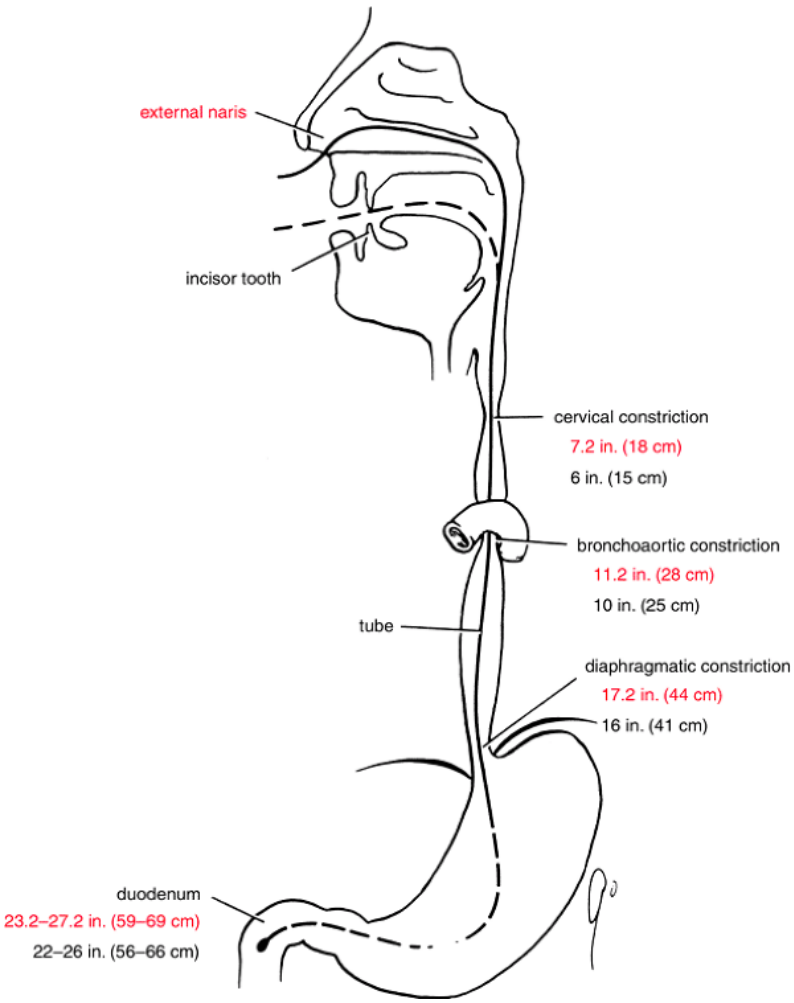

STOMACH

LOCATION AND DESCRIPTION:

- The dilated portion of the alimentary canal
- Situated in upper part of abdomen
- Extending from beneath left costal margin region into epigastric and umbilical regions
- Relatively fixed at both ends, very mobile in between

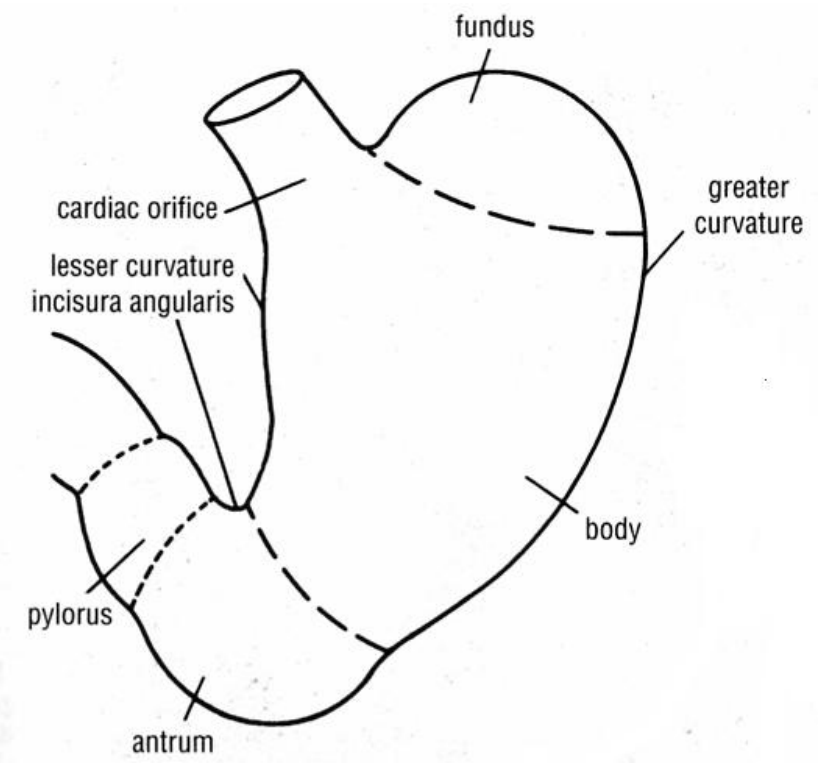

Shapes of the stomach:

J-shaped stomach: Elongated vertically in the tall thin person

Steer-horn stomach: High and transversely arranged in the short, obese person

STOMACH

has:

2 openings: Cardiac and pyloric orifices

2 curvatures: Greater and lesser curvatures

2 surfaces: Anterior and posterior surfaces

Parts of the stomach:

Fundus: Dome-shaped, projects upward and to left of cardiac orifice, usually full of gas

Body: Extends from level of cardiac orifice to level of *incisura angularis* (constant notch in lower part of lesser curvature)

Pyloric antrum: from incisura angularis to pylorus

Pylorus: Tubular part of the stomach, has thick muscular wall (pyloric sphincter) and its cavity called pyloric canal and lies on *transpyloric plane*

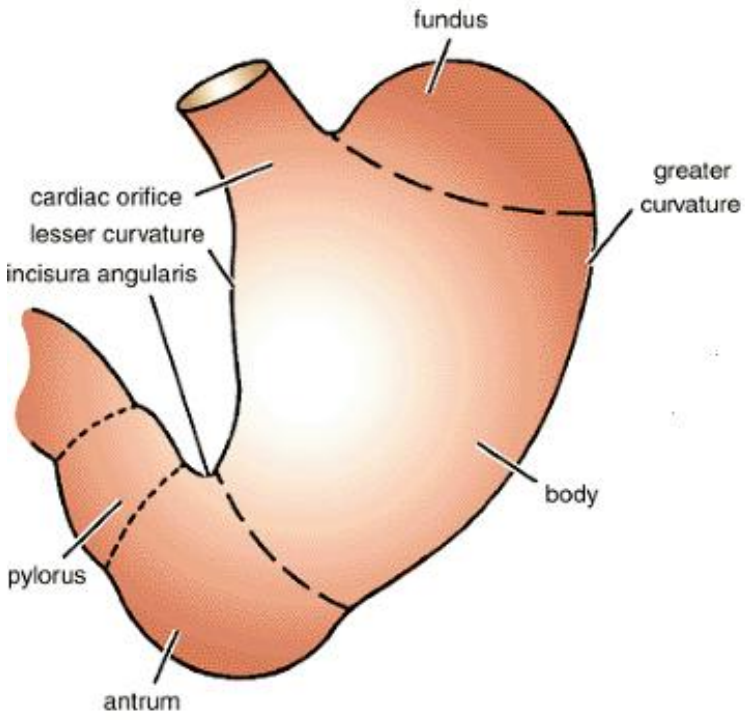

STOMACH

Lesser curvature:

- Forms right border of stomach
- Extends from cardiac orifice to pylorus
- Suspended from liver by lesser omentum

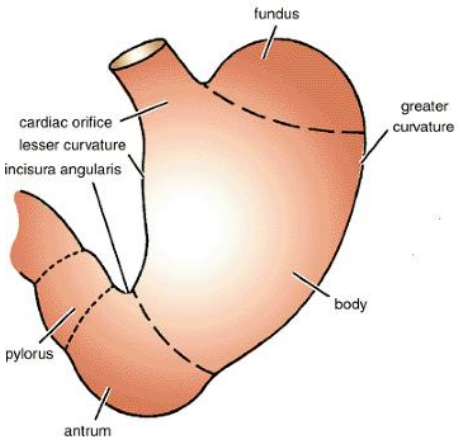

Greater curvature:

- Much longer than lesser curvature.
- Extends from left of cardiac orifice, over dome of the fundus and along left border of the stomach to the pylorus.

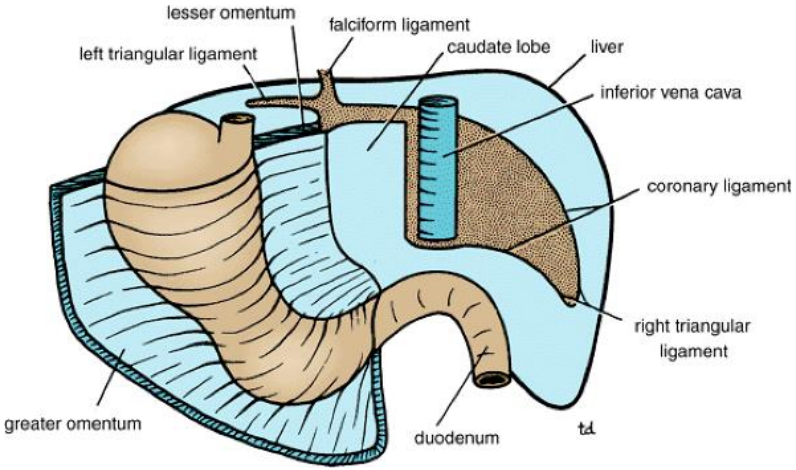

Gastrosplenic ligament: Extends from its upper part to the spleen

Greater omentum: Extends from its lower part to transverse colon.

Cardiac orifice:

- Where abdominal part of esophagus enters the stomach.
- Has no anatomical sphincter, but has physiological mechanism to prevent regurgitation of stomach contents into esophagus.

Pyloric orifice:

- Formed by the pyloric canal.
- About 1 inch (2.5 Cm) long.
- Circular muscle coat of stomach is thicker here forming anatomical and physiological sphincter (controls rate of discharge of stomach contents into duodenum).
- Can be recognized by slight constriction on surface of the stomach.

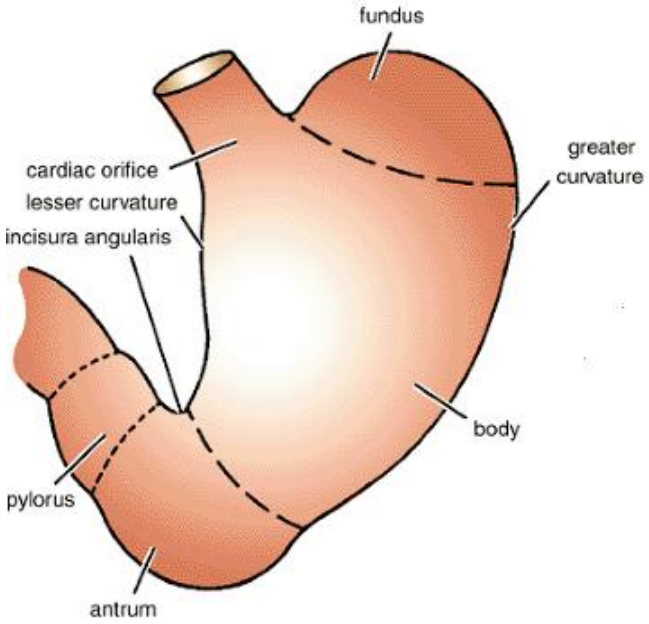

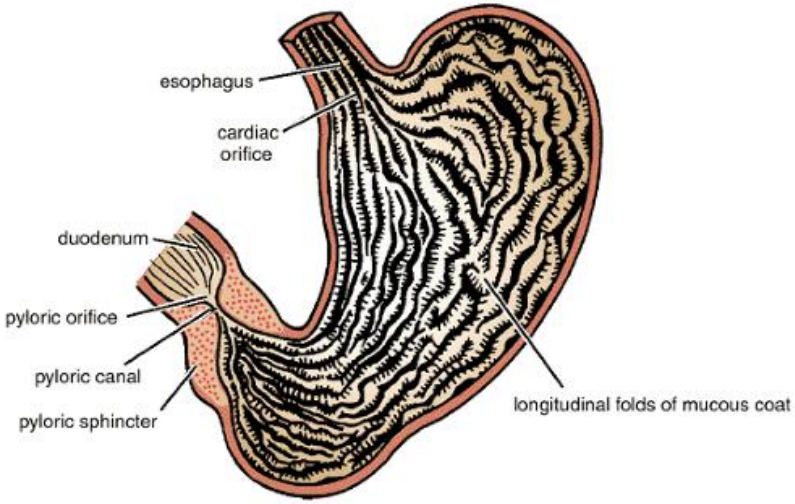

Mucous membrane of the stomach:

- Thick and vascular
- Thrown into mucous folds (rugae), mainly longitudinal in direction
- The folds flatten when stomach distended

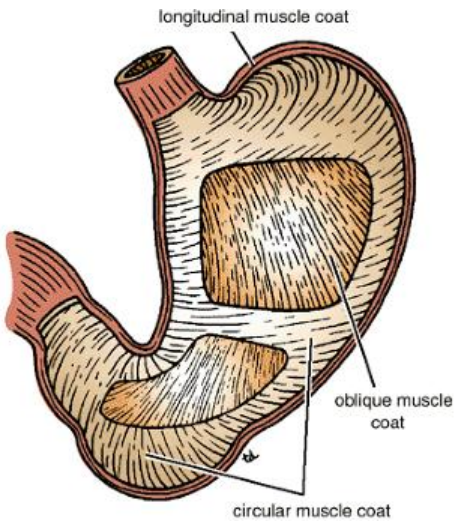

Functions of the stomach:

1. Storage of food (about 1500 ml in adult)
2. Mixes food with gastric secretions to form semifluid chyme
3. Controls rate of delivery of chyme to small intestine for efficient digestion and absorption

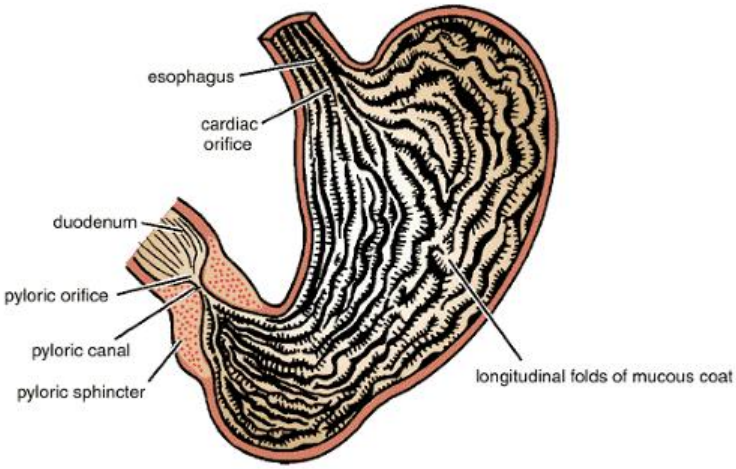

Relations of Stomach:

Anteriorly:

1. Anterior abdominal wall
2. Left pleura and lung
3. Left lobe of the liver
4. Left costal margin
5. Diaphragm

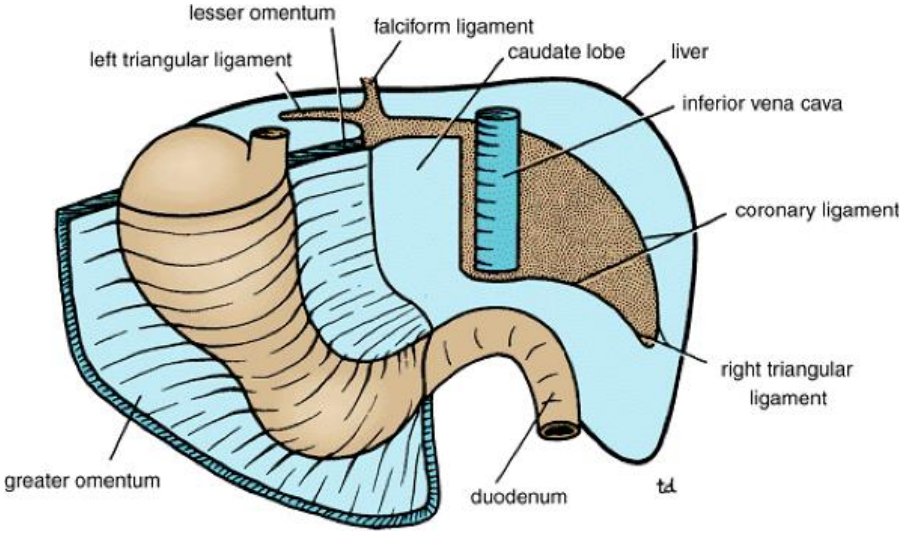

Posterior relations of the stomach (stomach bed):

1. Lesser sac
2. Diaphragm
3. Spleen
4. Left suprarenal gland
5. Upper part of left kidney
6. Splenic artery
7. Pancreas
8. Transverse mesocolon
9. Transverse colon
10. Greater sac (separates spleen from stomach)

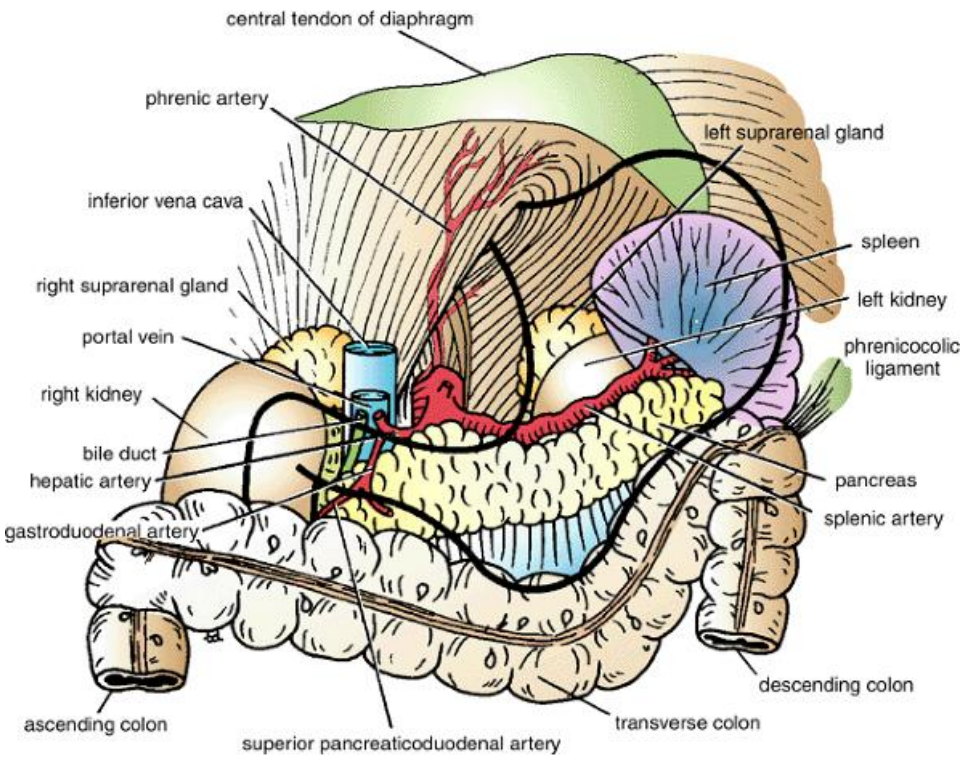

Arterial supply of stomach: (celiac trunk)

1. Left gastric artery: Branch of celiac trunk

- **Supplies lower part of esophagus and upper left part of stomach.**

2. Right gastric artery: Branch of hepatic artery

- **Supplies lower right part of stomach**

3. Short gastric arteries: Branches from splenic artery.

- **Pass in gastrosplenic omentum, supply fundus.**

4. Left gastroepiploic artery: Branch from splenic artery.

- **Pass in gastrosplenic omentum.**
- **Supplies upper part of greater curvature.**

5. Right gastroepiploic artery: From gastroduodenal artery.

- **Supplies lower part of greater curvature of stomach.**

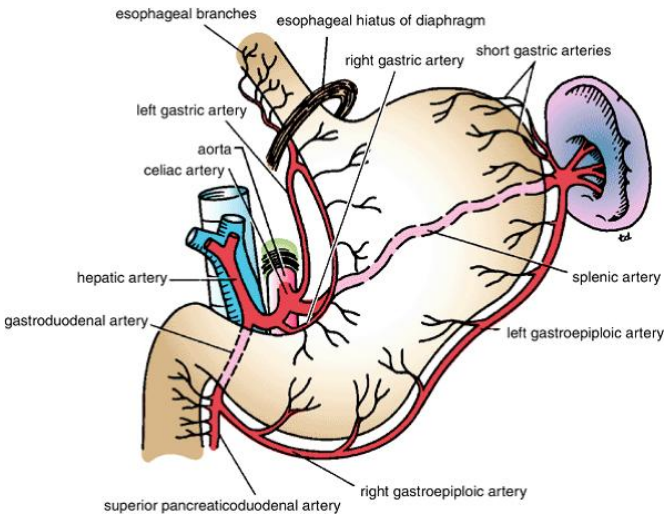

Venous Drainage of the Stomach:
(Drain into portal vein)

1. **Left gastric vein: Portal vein**
2. **Right gastric vein: Portal vein**
3. **Short gastric veins: Splenic vein**
4. **Left gastroepiploic vein: Splenic vein**
5. **Right gastroepiploic vein: Superior mesenteric vein**

LYMPH DRAINAGE: Foregut

❖Follow the arteries to celiac lymph nodes.

❖Arranged in 4 main groups:

1. Lymph nodes along left gastric vessels, their efferents pass to celiac nodes
2. Lymph nodes along right gastric vessels, their efferents pass to nodes along hepatic artery, then to celiac nodes.
3. Lymph nodes along short gastric arteries and left gastroepiploic artery, then into lymph nodes at hilum of spleen. From there, to pancreaticosplenic nodes along splenic artery, drain into celiac nodes.
4. Right gastroepiploic nodes, their efferents join nodes along gastroduodenal artery, drain into celiac nodes.

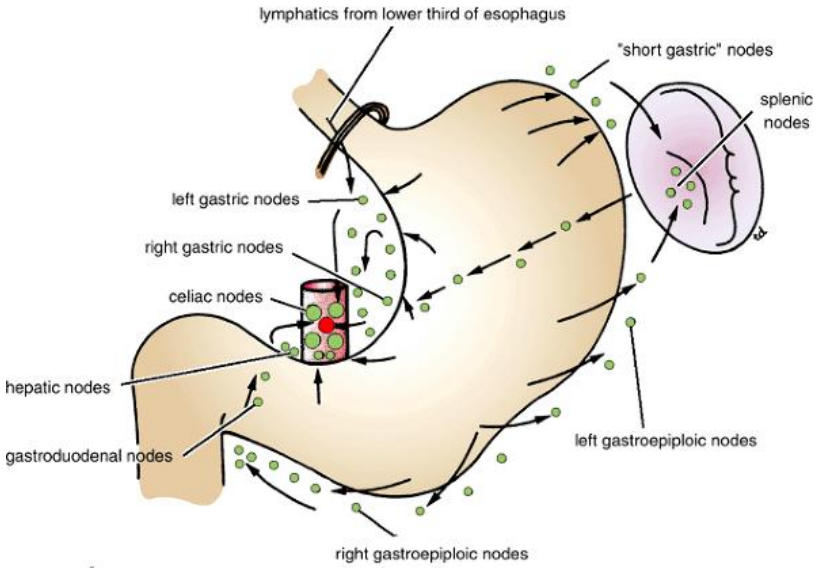

NERVE SUPPLY OF STOMACH:

Derived from:

1. Celiac sympathetic plexus
2. Right and left vagus nerves (parasympathetic)

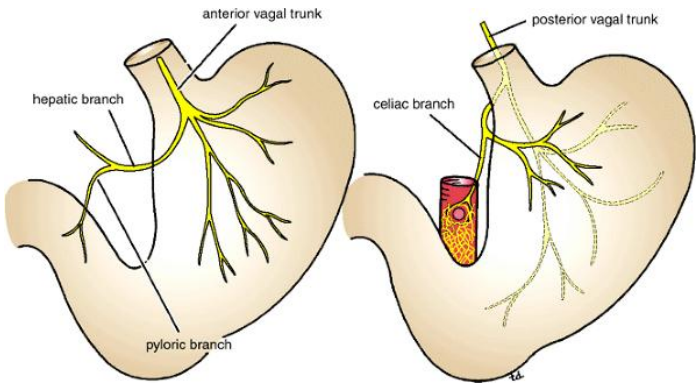

Anterior vagal trunk:

- Formed mainly from left vagus
- Enters abdomen with esophagus
- Supplies anterior surface of stomach
- Hepatic branch to liver and pyloric branch to pylorus

Posterior vagal trunk:

- Formed mainly from right vagus
- Enters abdomen with esophagus
- Supplies mainly posterior surface of stomach
- Passes to celiac and superior mesenteric plexuses, distributed as far as splenic flexure and to pancreas.

THANK YOU